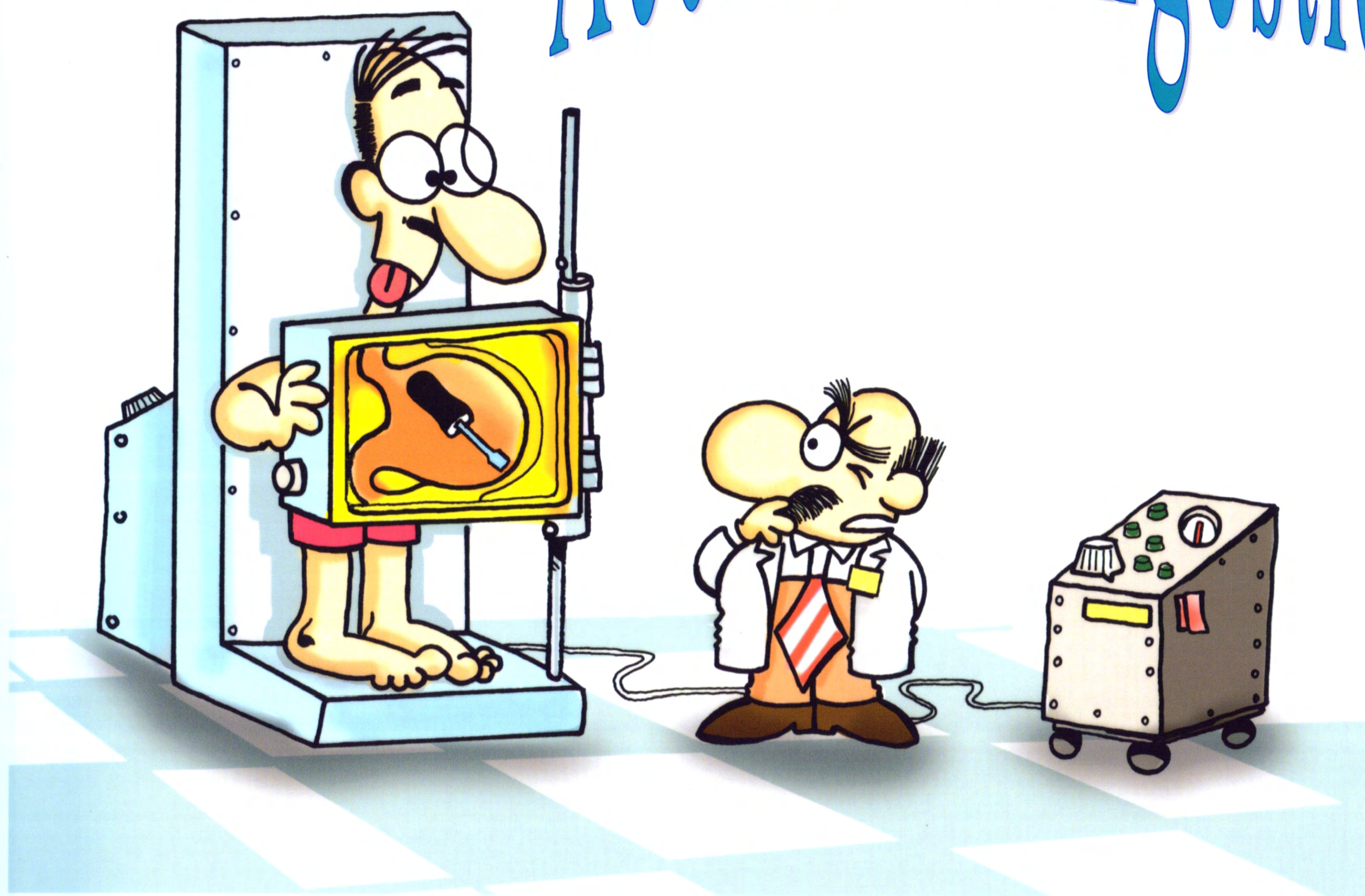


# Accidental Ingestion of a Screwdriver



**Prof. Hernández Montero Sofía<sup>1</sup>, Sánchez Pardo M<sup>2</sup>, Celada González A<sup>2</sup>, Boyer Quesada F<sup>2</sup>, Gracia García E<sup>2</sup> Hernández Herrera M<sup>2</sup>, Prof. Lorrio Castro JM<sup>3</sup>.**

**1 Oral and Maxillofacial Surgeon – Director of Master of Oral Implantology and Prothesis University Alfonso X El Sabio Madrid, Private Practice Zaragoza Spain**

**2 Dentistry, Students Master of Oral Implantology and Prothesis, University Alfonso X El Sabio Madrid Spain**

**3 Dentistry, Professor Master of Oral Implantology and Prothesis, University Alfonso X El Sabio Madrid Spain**

[drsofiay@yahoo.com](mailto:drsofiay@yahoo.com)  
[www.headandneck.es](http://www.headandneck.es)



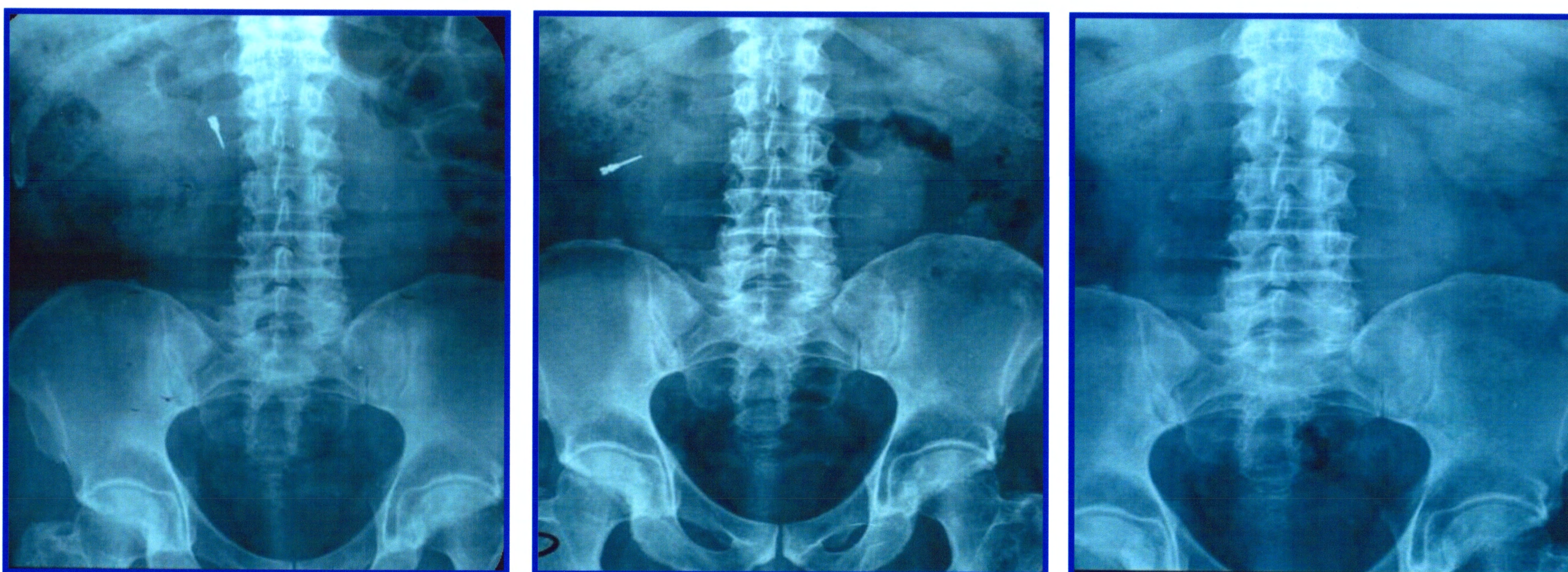## INTRODUCTION

Ingestion of dental material is not as unusual as aspiration is, and even if does not cause most of the cases any clinical signs or symptoms we should treat carefully our patients in order to avoid complications.

We have seen referred in the medical international literature several cases of aspiration or ingestion of dental material with different clinical complication and morbidity: esophagus perforation, mediastinal infection, gastrointestinal perforation, foreign body impaction and infection, acute airway obstruction with hypoxia and even death of the patient can happen .

## MATERIAL

We report a case of a 50 year old man who was under implants treatment. He suffered a cough access during the therapy and swallowed a dental implant screw-driver. X-ray study and close follow up was performed. The patient had not gastrointestinal or other complication and the implant treatment was completed.



Abdominal x- ray showing a foreign body displacement

## CONCLUSION

Aspiration is a severe complication that sometimes occurs during dental treatment and can it cause even the death or the patient. Foreign dental material ingestion has also a low incidence and not so terrible consequences, but with every patient we have in our hands it is mandatory during dental treatment, and more in the case of students, the use of all preventive measures such floss ligatures around the dental implant screw-drivers, correct position of the patient, rubber dams, etc..., to avoid adverse outcomes.