

# HOSPITAL "MIGUEL SERVET" OF ZARAGOZA

## DEPARTMENT OF ORAL AND MAXILLOFACIAL SURGERY

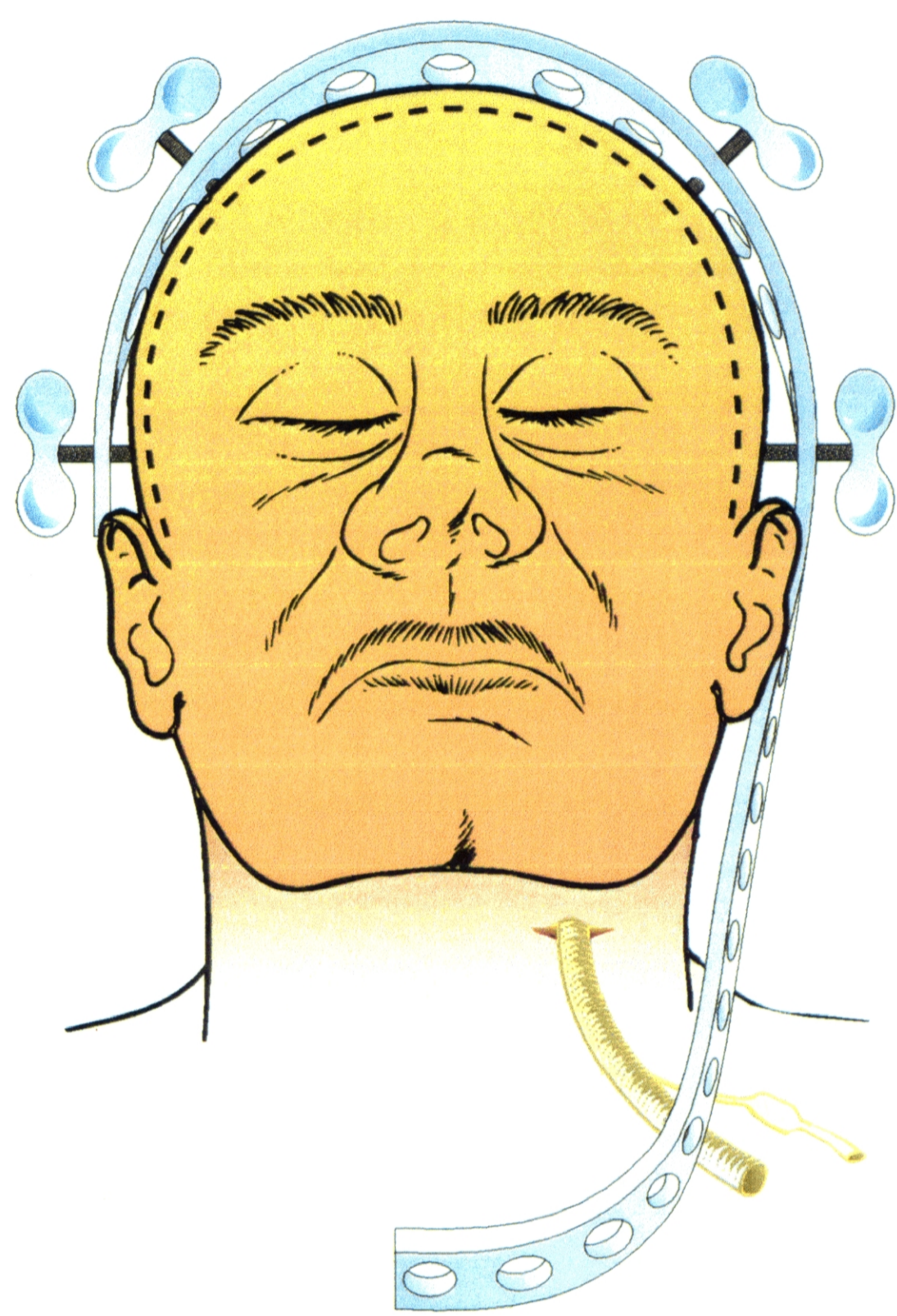
HEAD OF THE DEPARTMENT

FRANCISCO HERNANDEZ ALTEMIR, M.D.

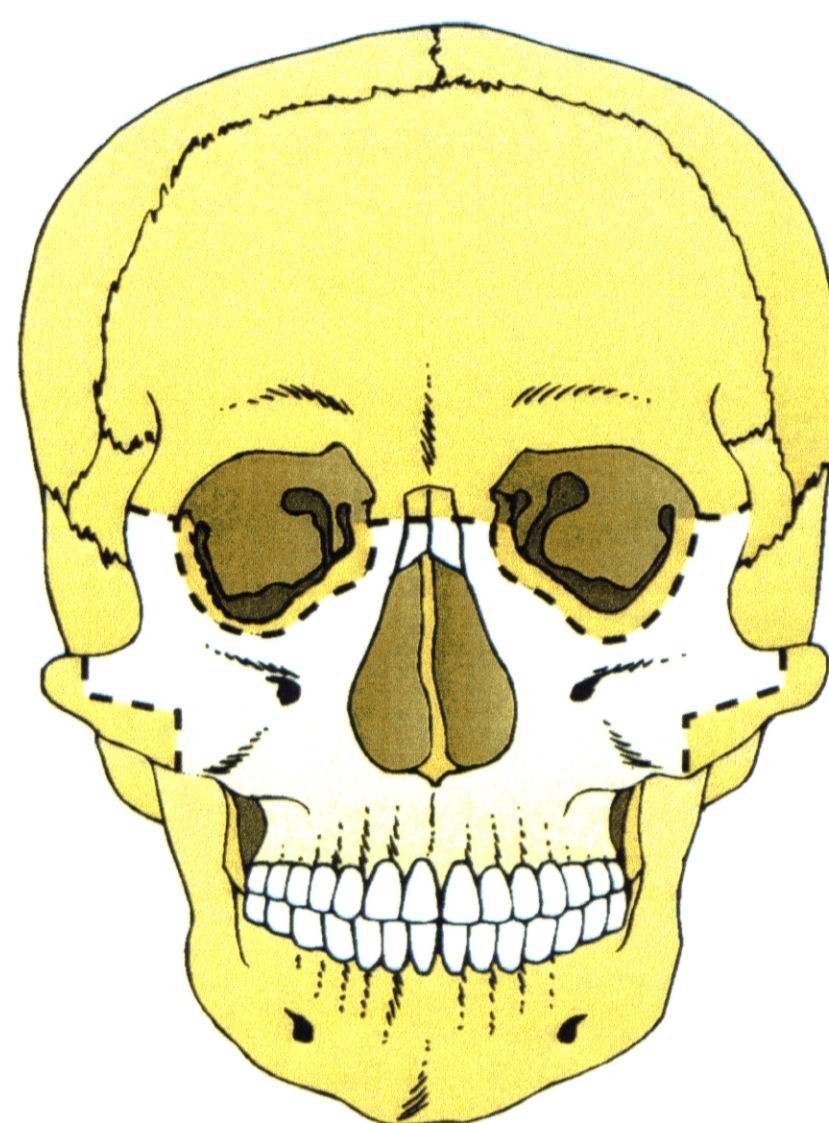
### "CRANIOFACIAL TRACTION ARCH A NEW DEVICE"

FRANCISCO HERNANDEZ ALTEMIR, M.D.

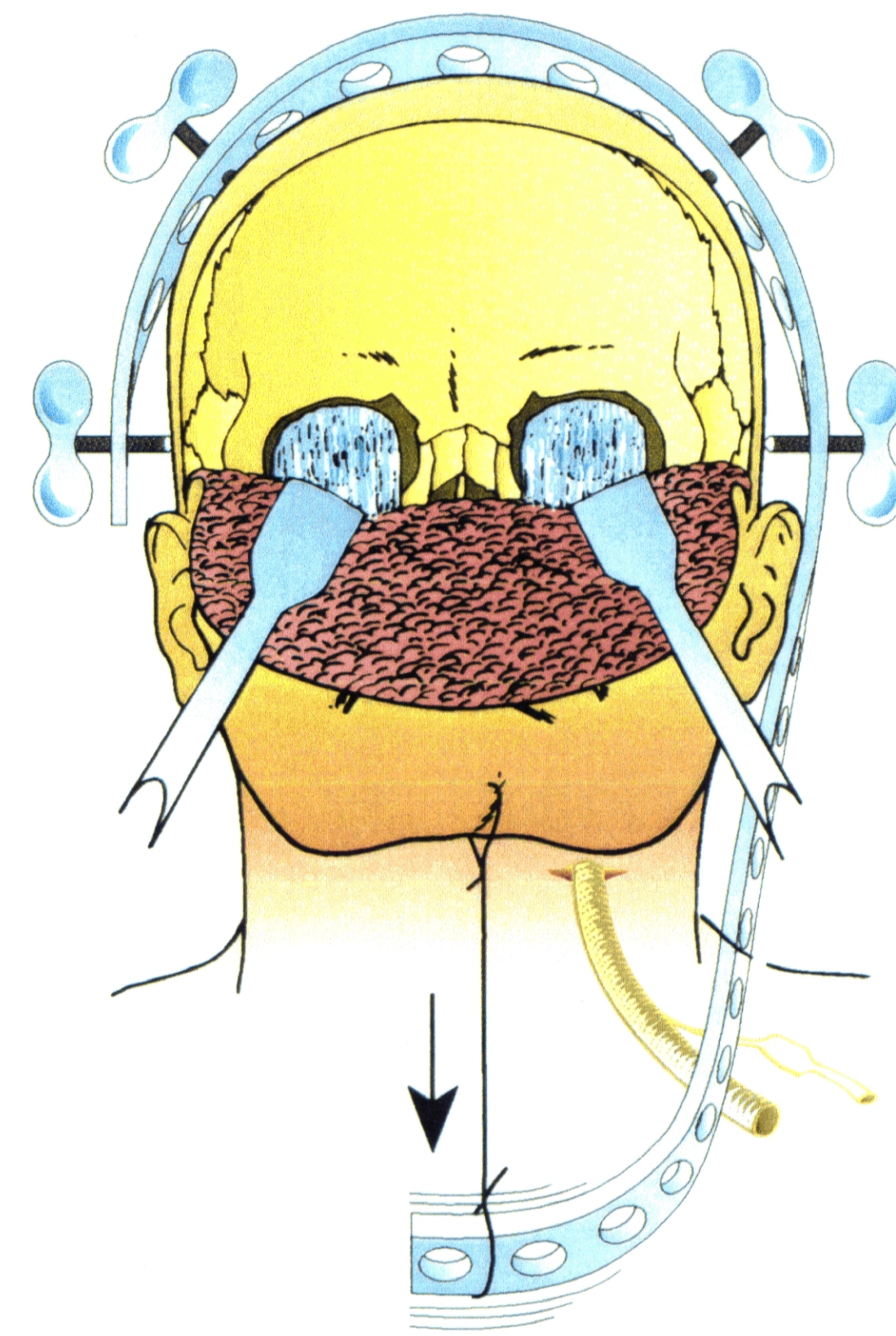
Access to the skull base by means of Le Fort III Osteotomy through a coronal incision.  
Craniofacial Traction Arch and Submental Intubation.



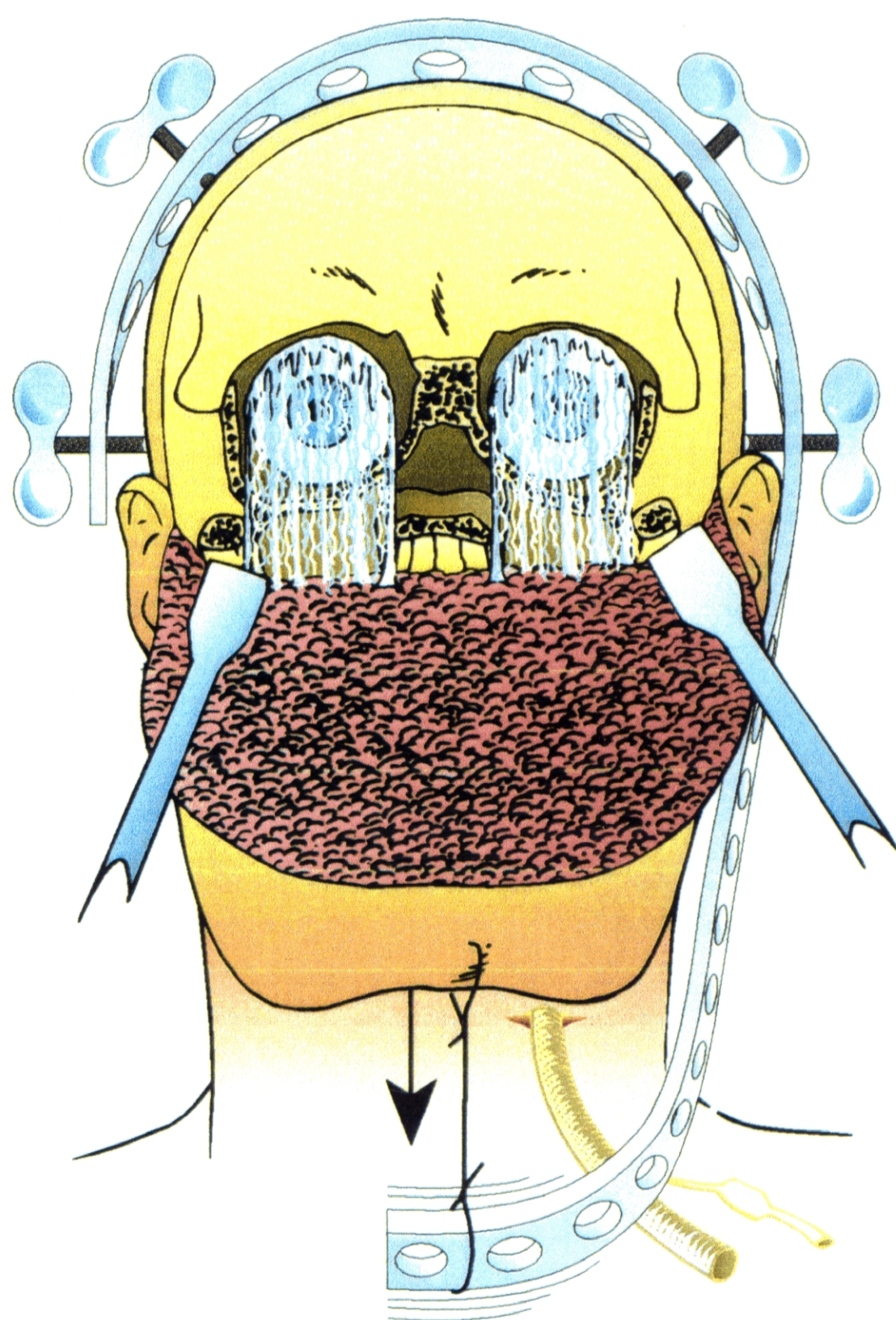
**Fig. 1** : Design of the incision, location of the Craniofacial Traction Arch and the Submental Intubation.



**Fig. 2** : Design of the Osteotomy of the type Le Fort III.



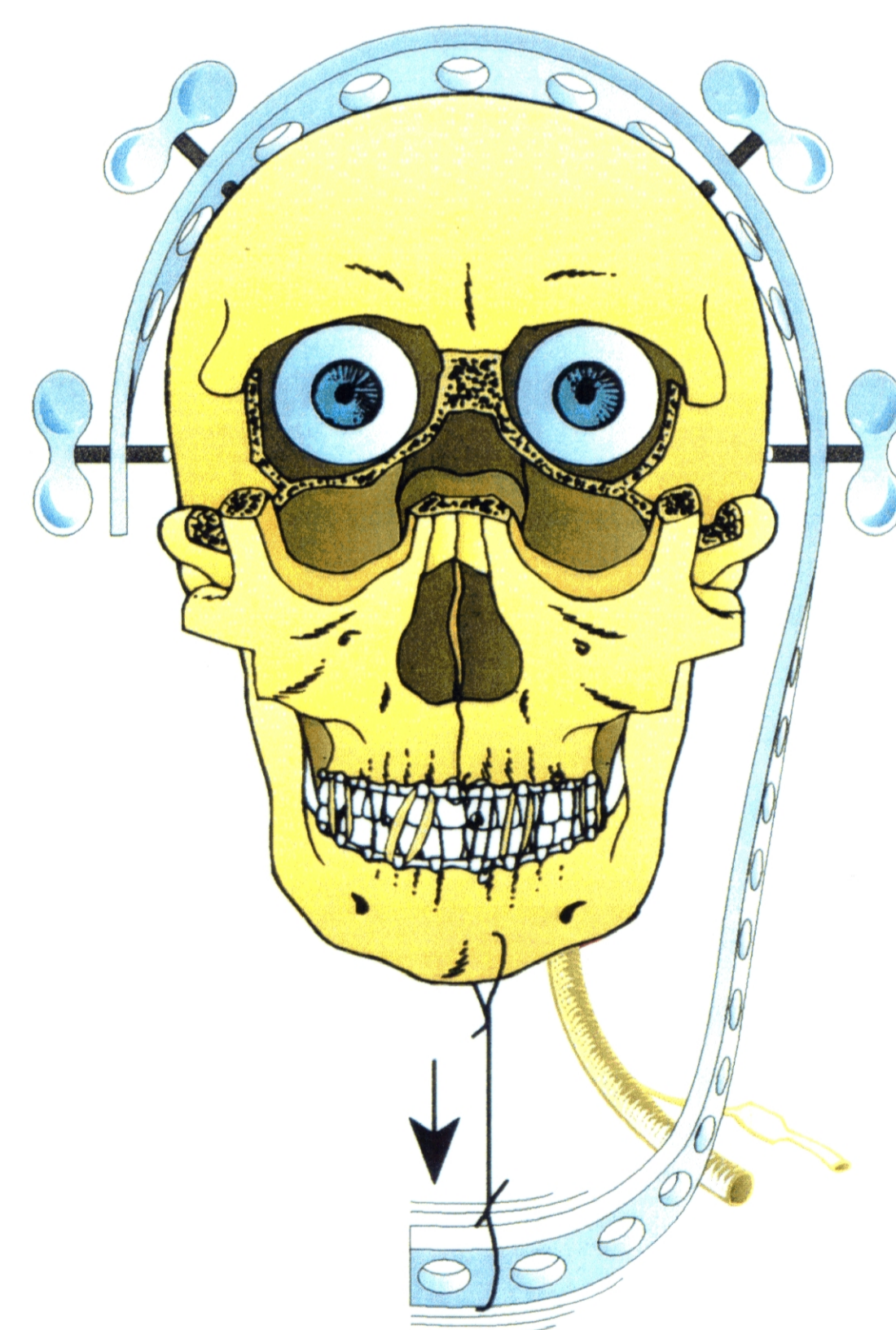
**Fig. 3** : Detachment of the pericranial flap in order to make the osteotomy.



**Fig. 4** : Look of the surgical area of subcranial predominance acquired by means of a craniofacial traction, intermaxillary blockade and submental intubation.

#### ACCESS TO THE SKULL BASE BY MEANS OF LE FORT III OSTEOTOMY THROUGH A CORONAL INCISION. CRANIOFACIAL TRACTION ARCH AND SUBMENTAL INTUBATION

It is with the aim of facilitating some surgical procedures in the area of oral and craniofacial surgery and making craniomandibular tactions in several congenital or acquired diseases (traumatism, oncological patients, etc.) that we have developed a Craniofacial Traction Arch.



**Fig. 5** : The flesh has been put aside to show more plainly our surgical procedure.

FIRST COMMUNICATION AT: SYMPOSIUM DISMANTLING AND REASSEMBLY OF THE FACIAL SKELETON-STATE OF THE ART-CASTELLANZA (VA)-NOVEMBER 26, 1994.  
Under the patronage of the EUROPEAN ASSOCIATION FOR CRANIOMAXILLOFACIAL SURGERY, EUROPEAN SKULL BASE AND ITALIAN SOCIETY FOR MAXILLOFACIAL SURGERY.

**XIII CONGRESO NACIONAL DE LA SOCIEDAD ESPAÑOLA DE CIRUGIA ORAL Y MAXILOFACIAL**  
PAMPLONA-IRUÑA 29-30-31 MAYO - DONOSTIA-SAN SEBASTIAN 31 MAYO - 1-2-3 JUNIO 1995

**THE XIV CONGRESS OF EUROPEAN ASSOCIATION FOR CRANIO-MAXILLOFACIAL SURGERY.**  
HELSINKI 1-5 SEPTEMBER 1998