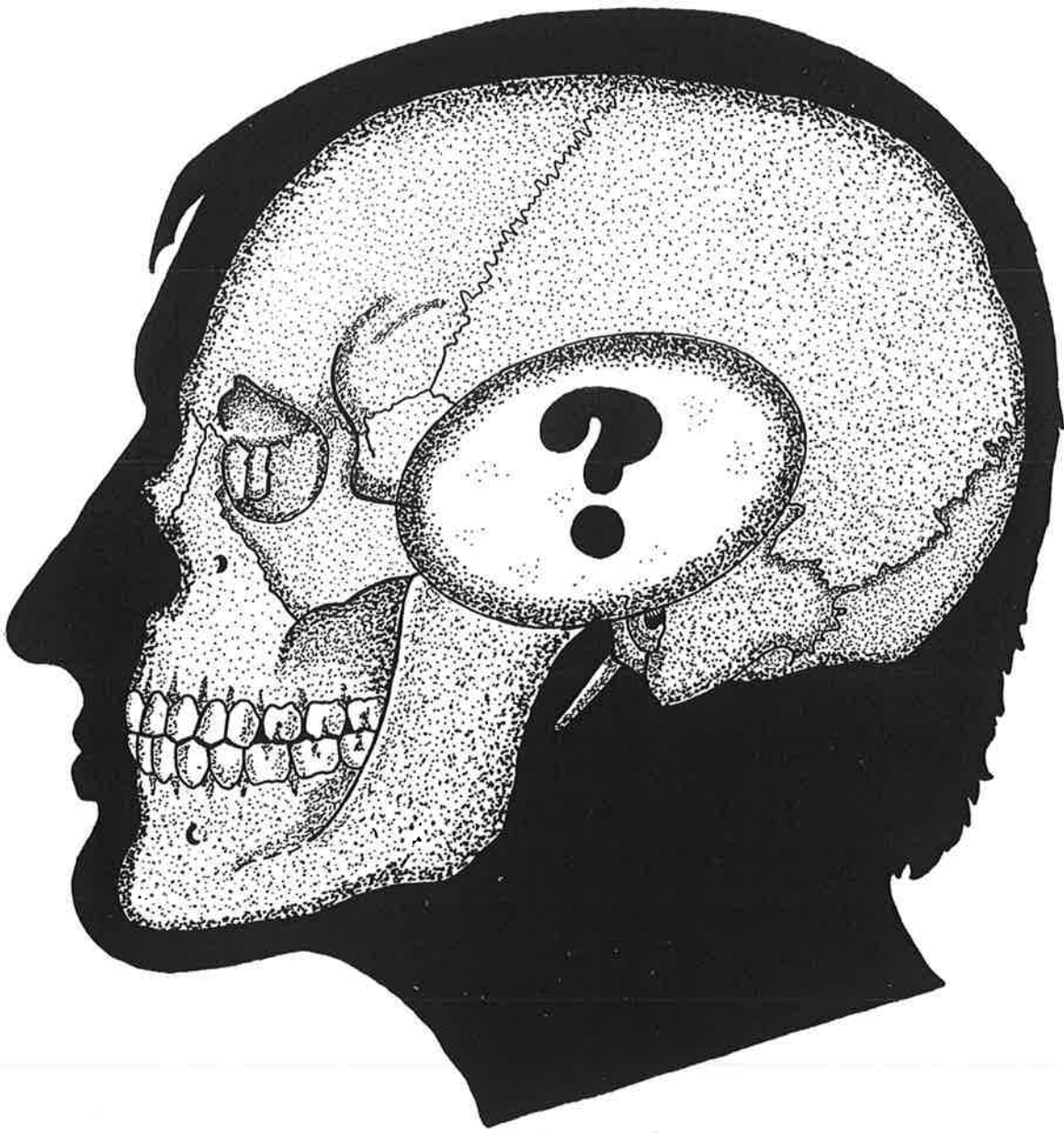

**ACCESO TRANSFACIAL
A LA REGION RETROMAXILAR**

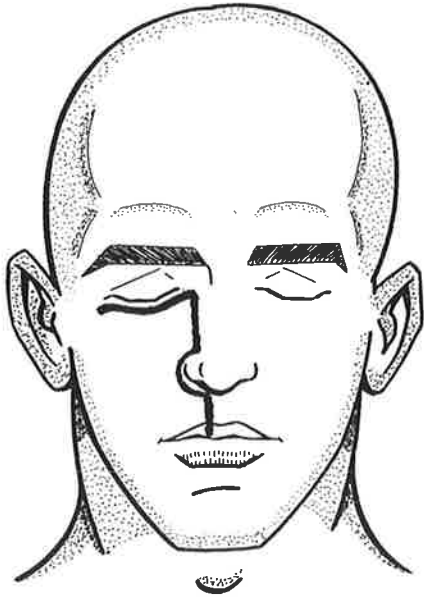


Figura 1

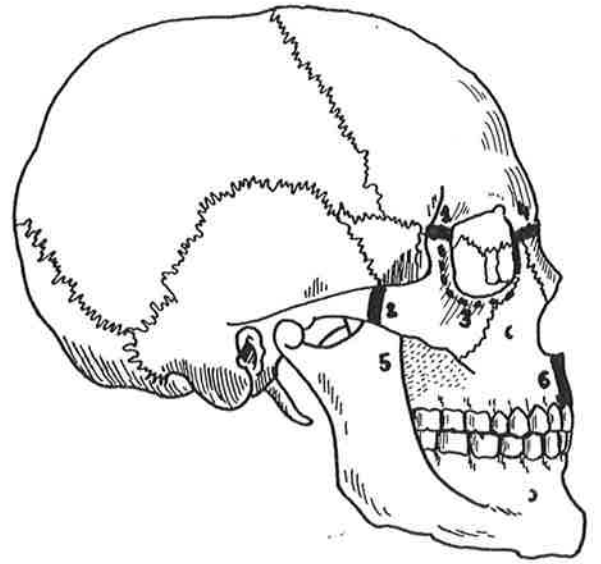


Figura 2

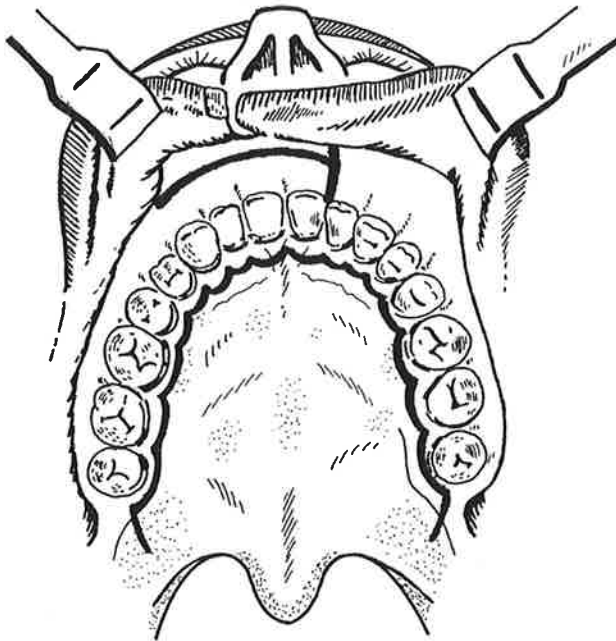


Figura 3

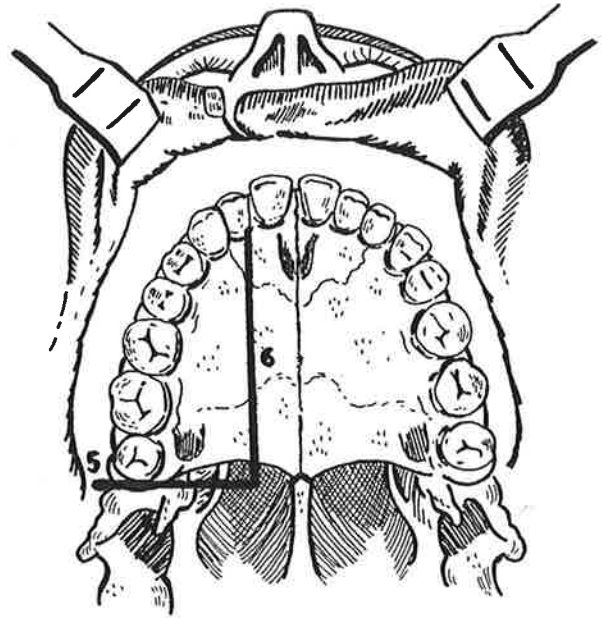


Figura 4

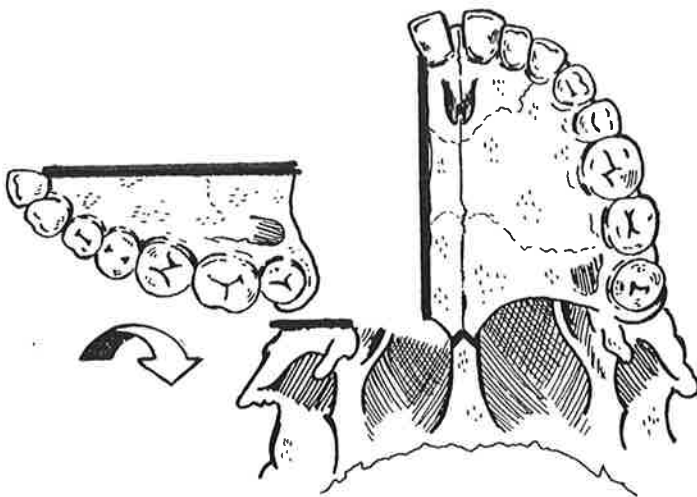


Figura 5

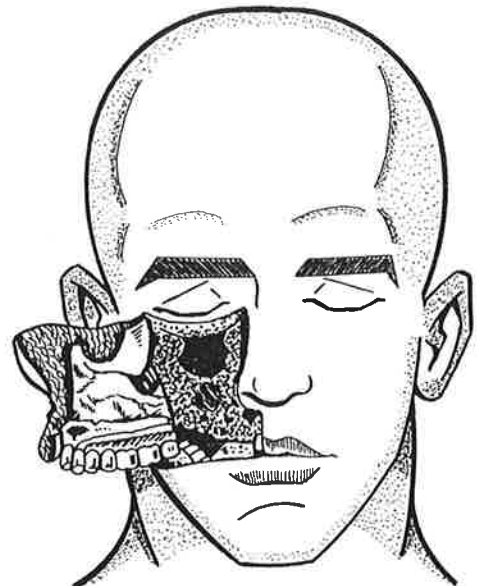


Figura 6

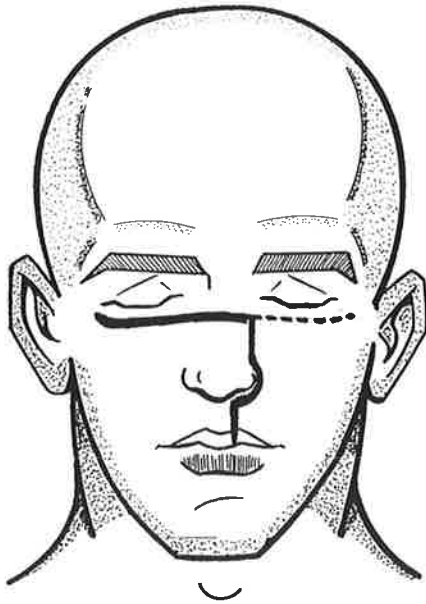


Figura 1

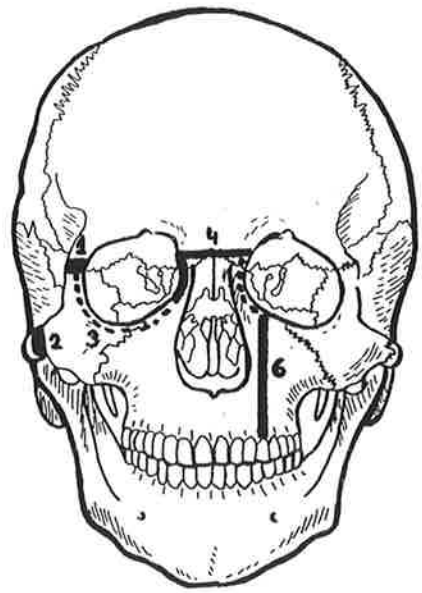


Figura 2

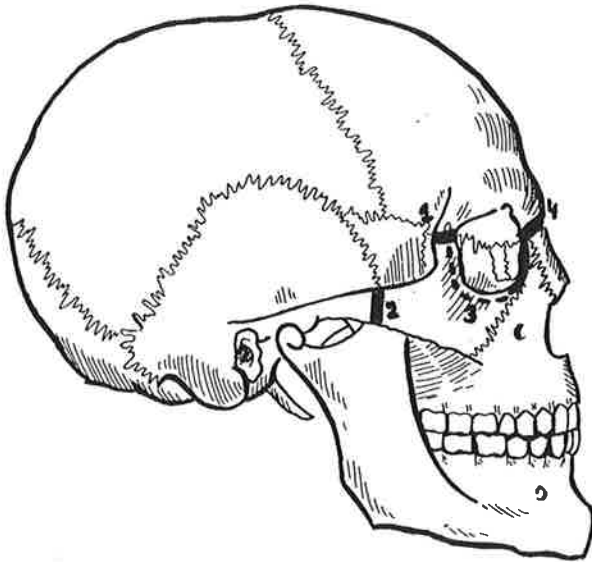


Figura 3

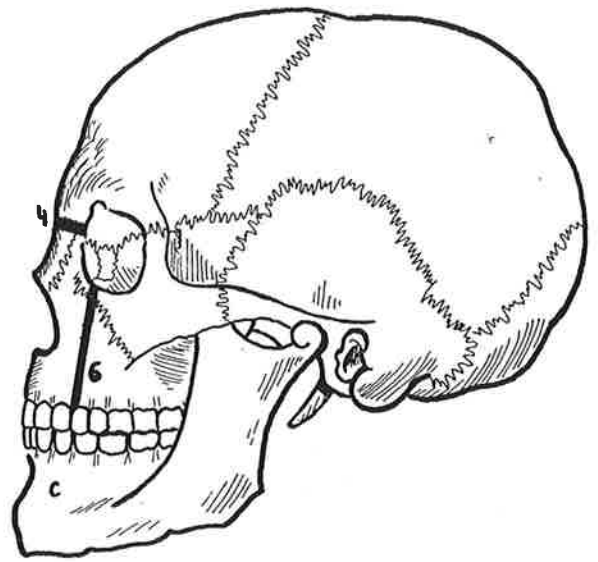


Figura 4

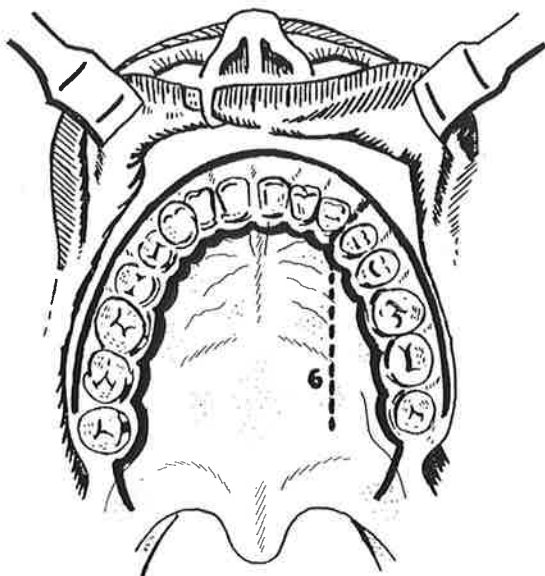


Figura 5

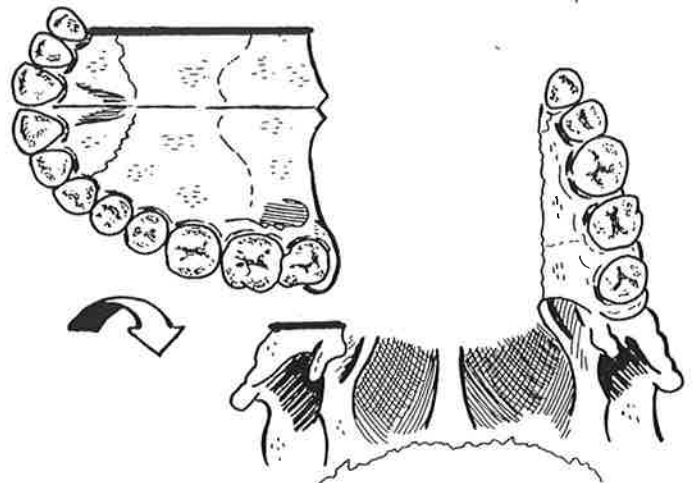


Figura 6

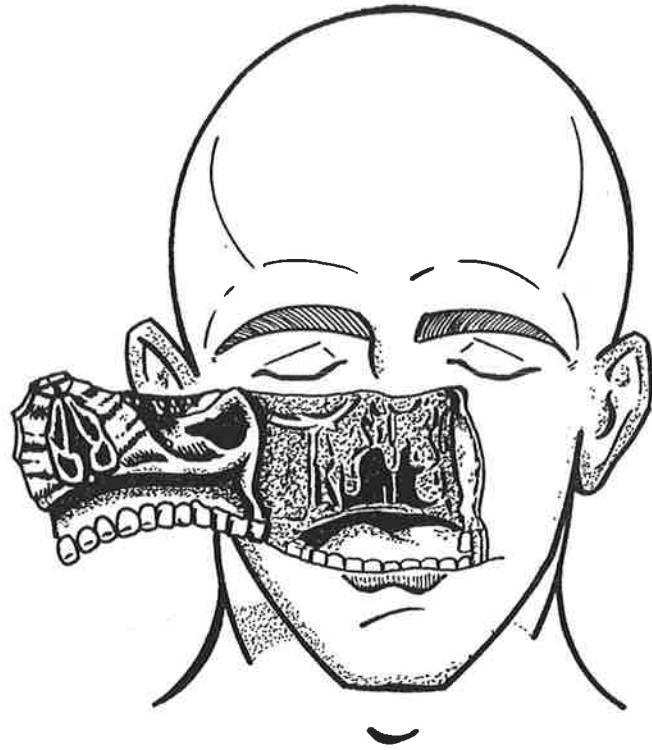


Figura 7

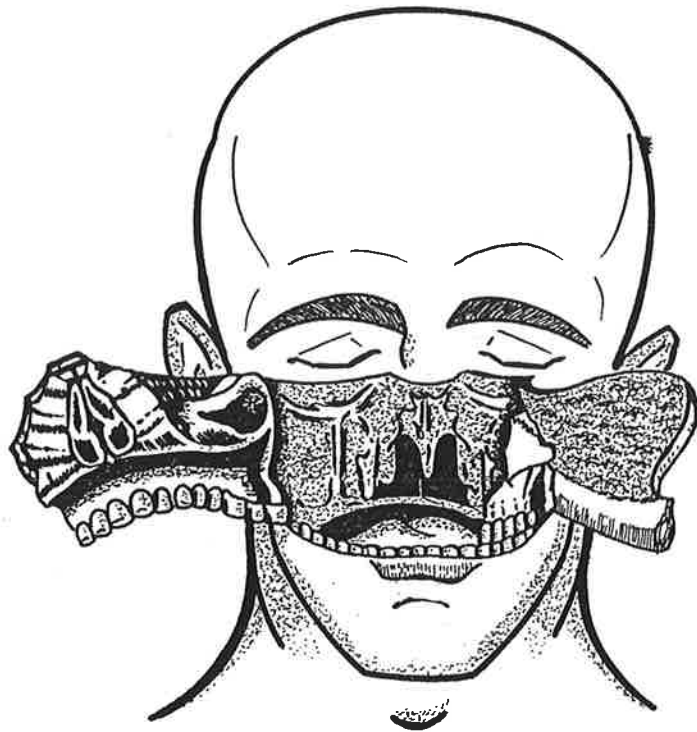


Figura 8

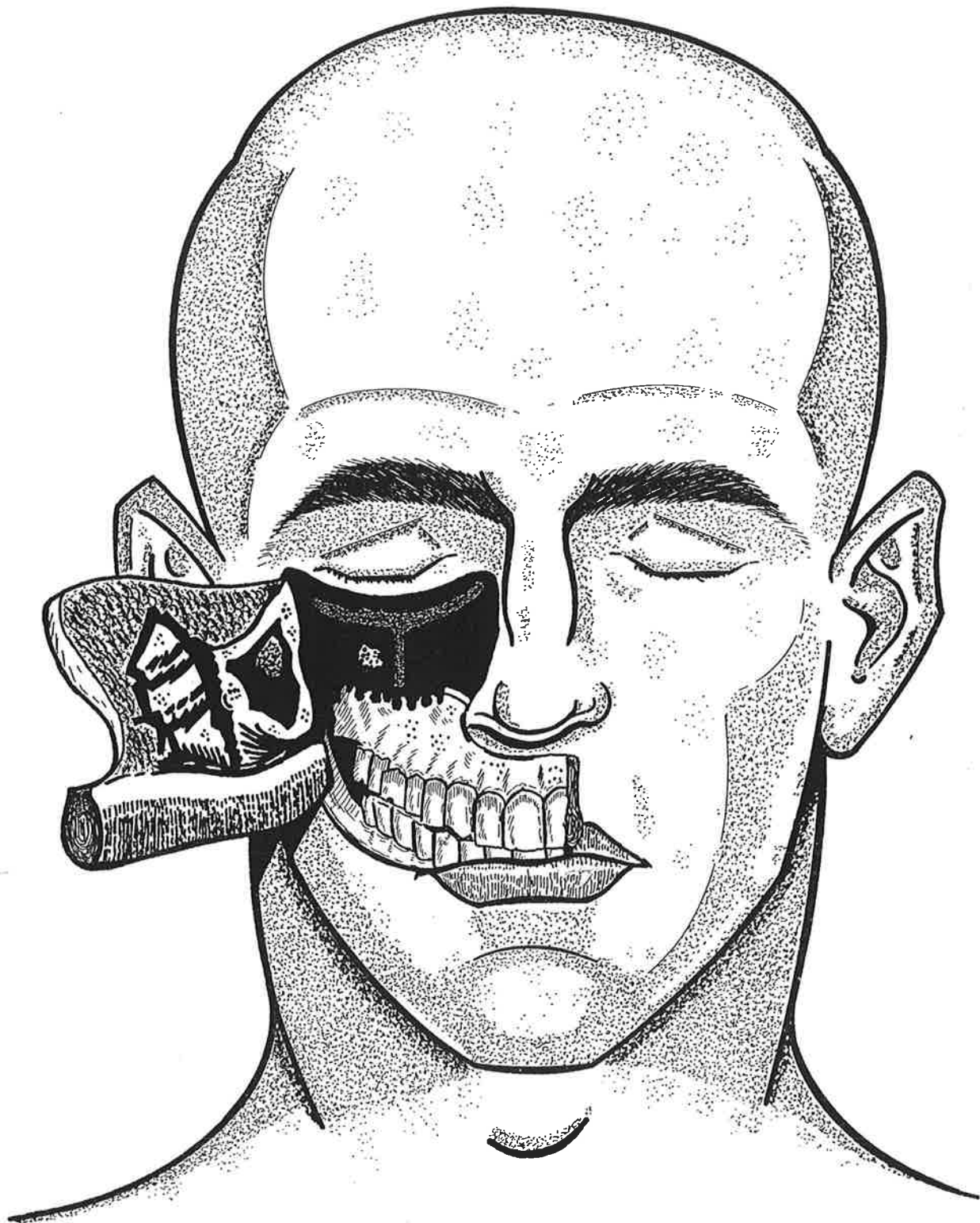


Figura 9

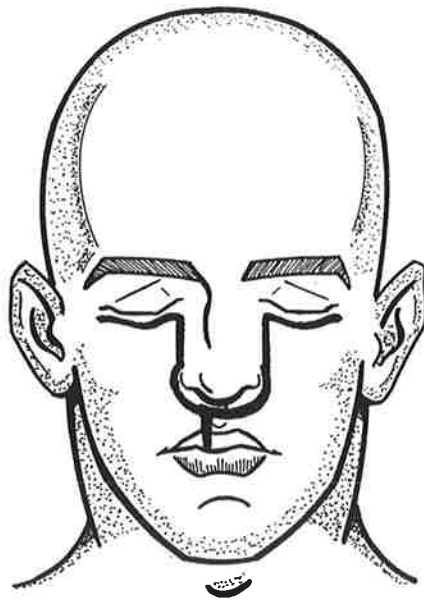


Figura 1

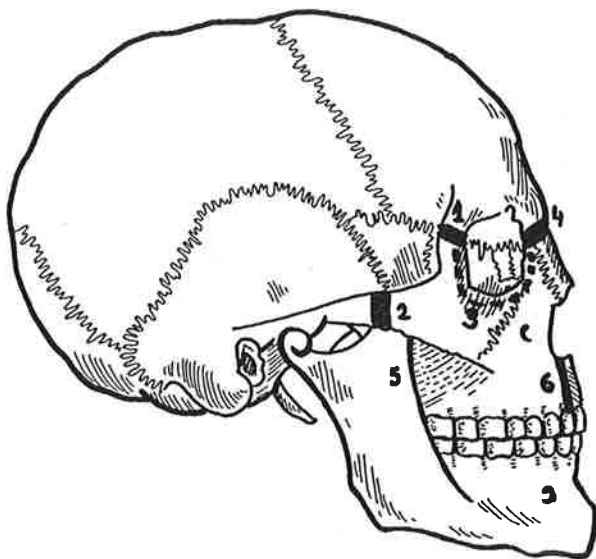


Figura 2

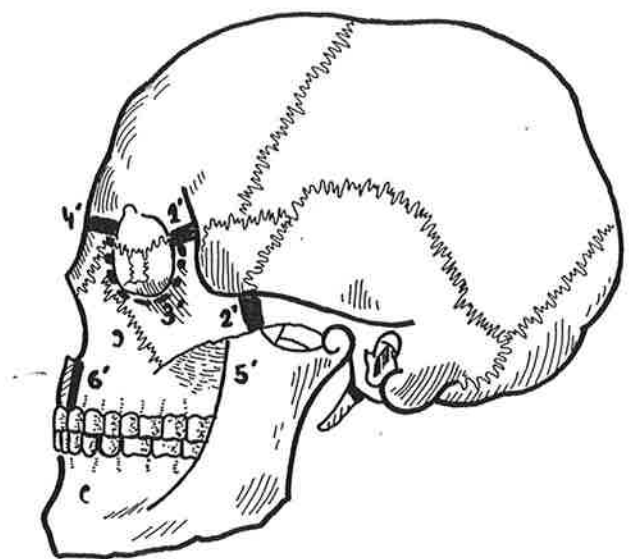


Figura 3

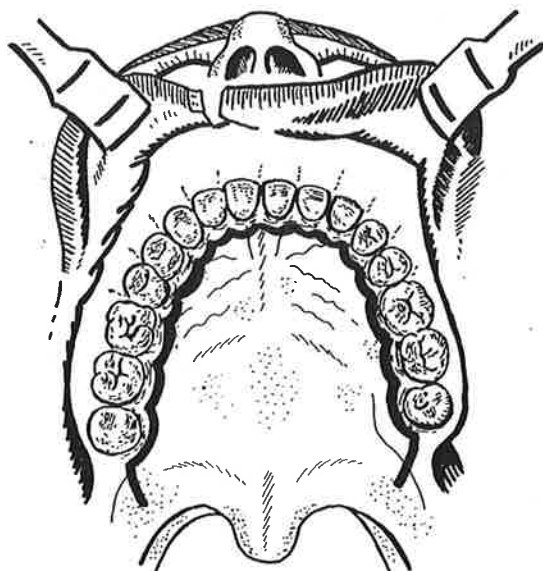


Figura 4

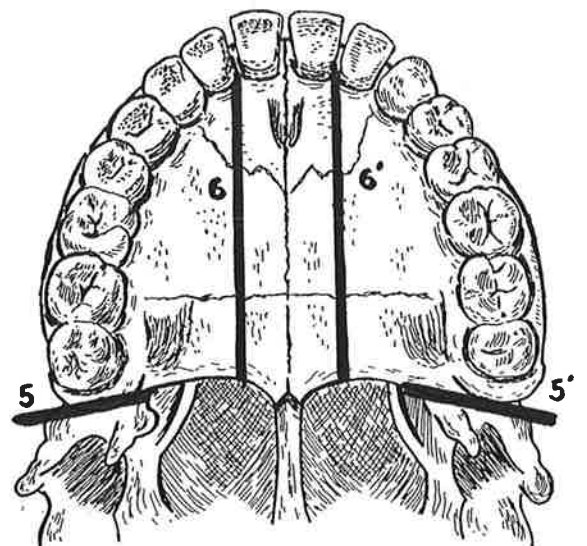


Figura 5

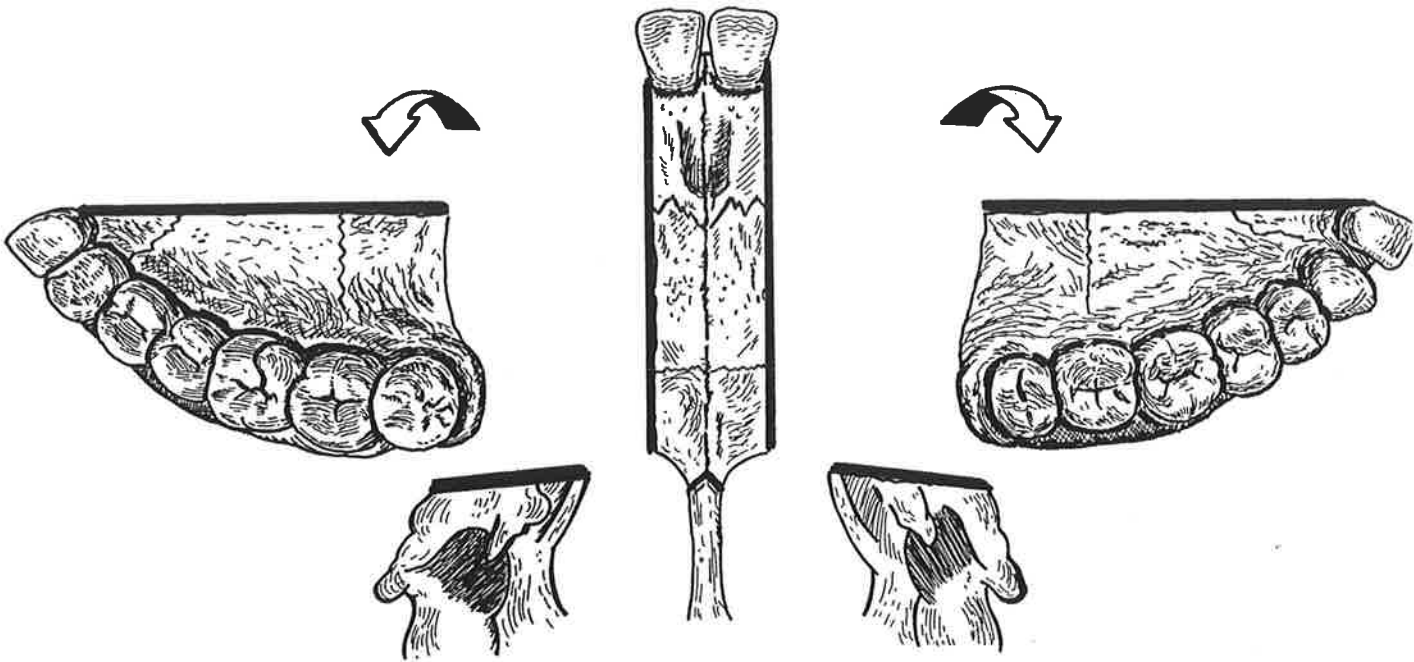


Figura 6

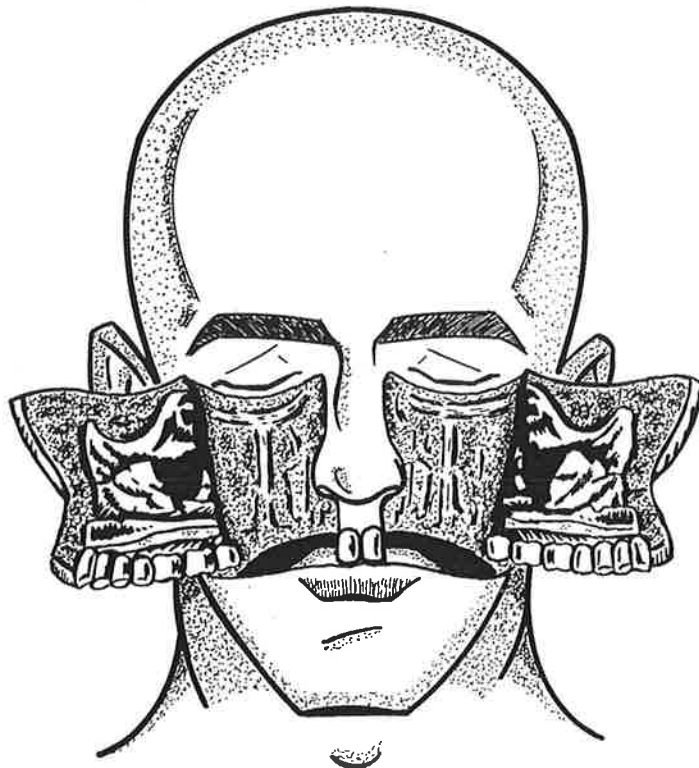


Figura 7

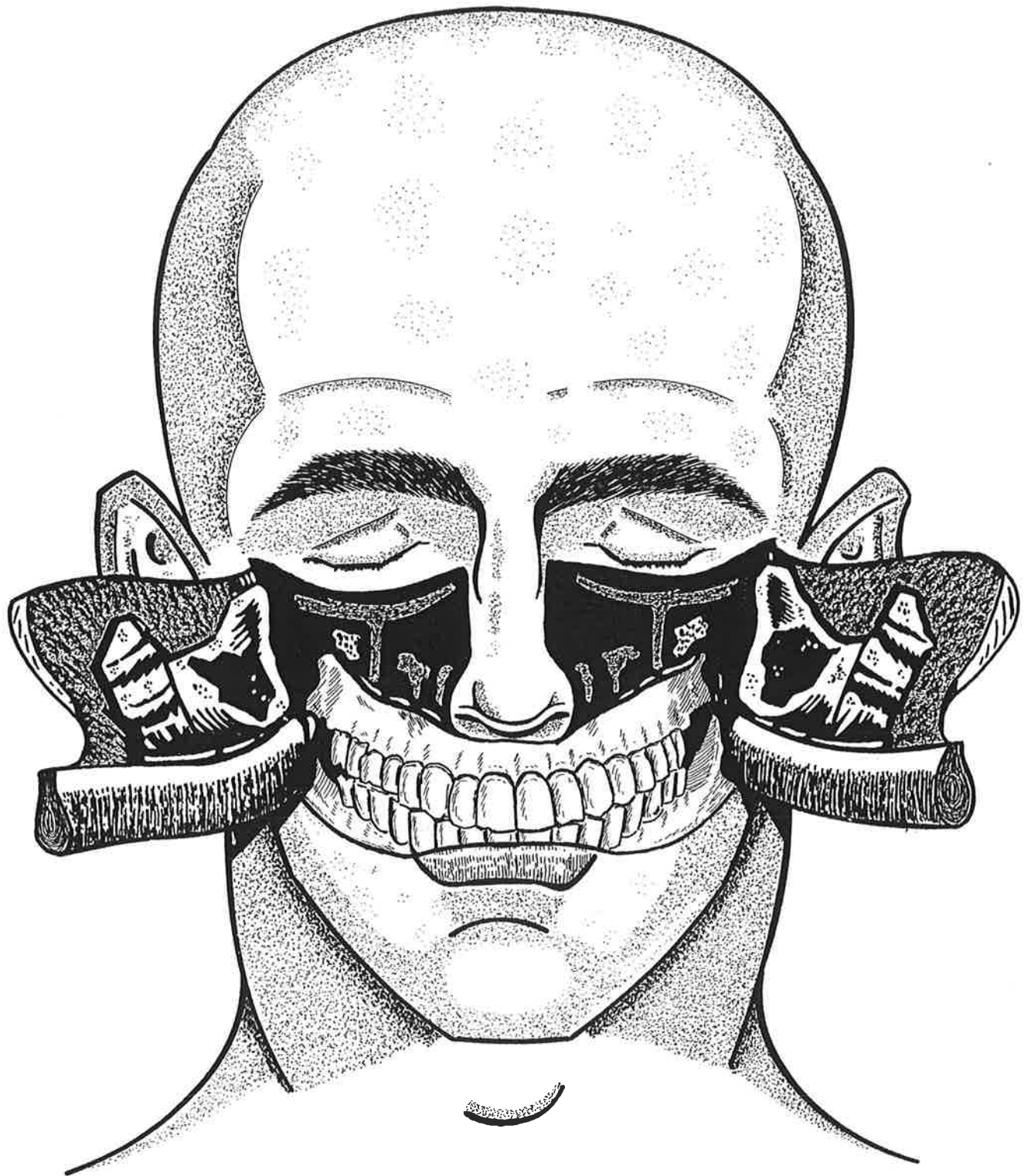


Figura 8

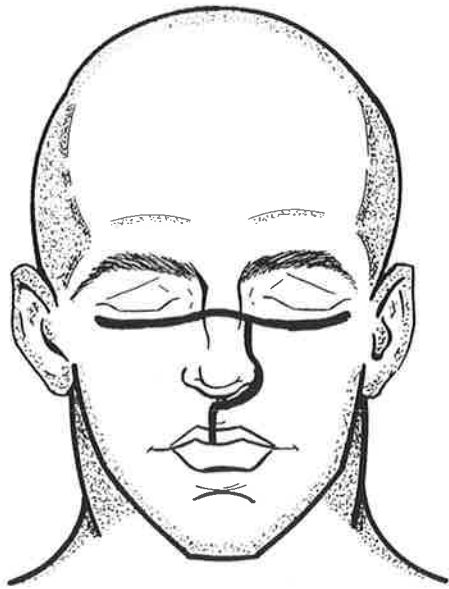


Figura 1

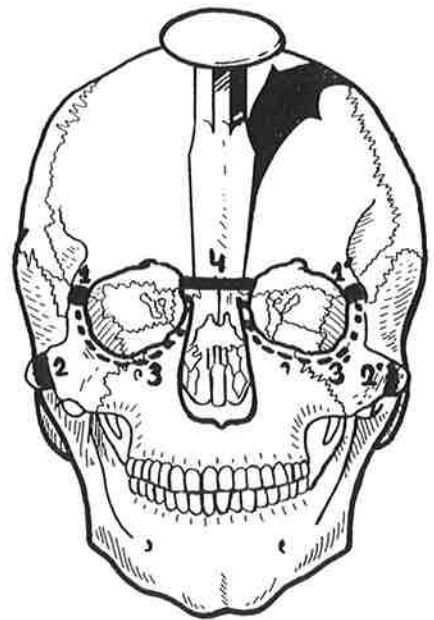


Figura 2

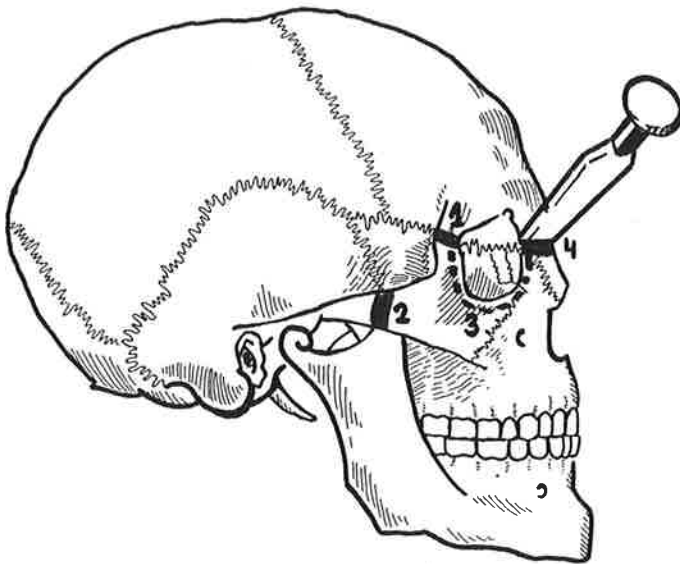


Figura 3

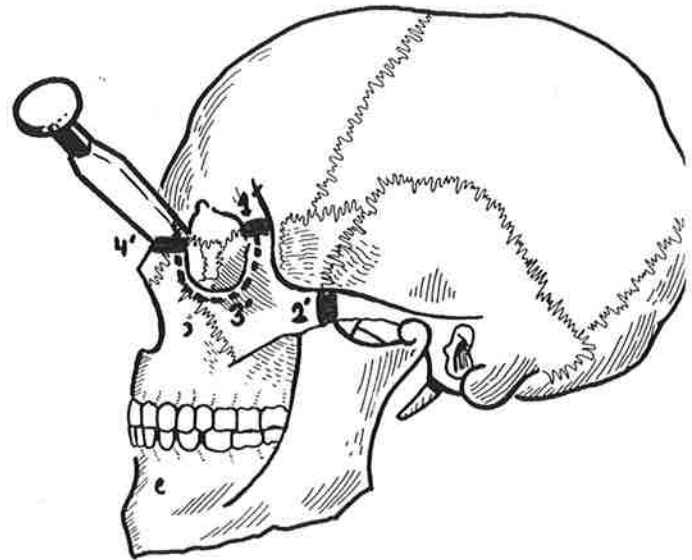


Figura 4

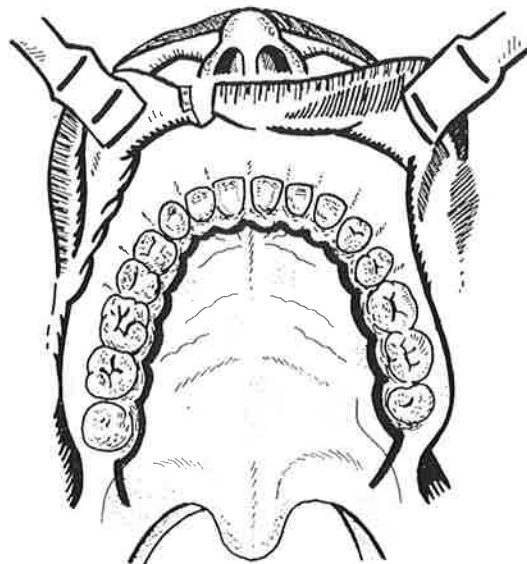


Figura 5

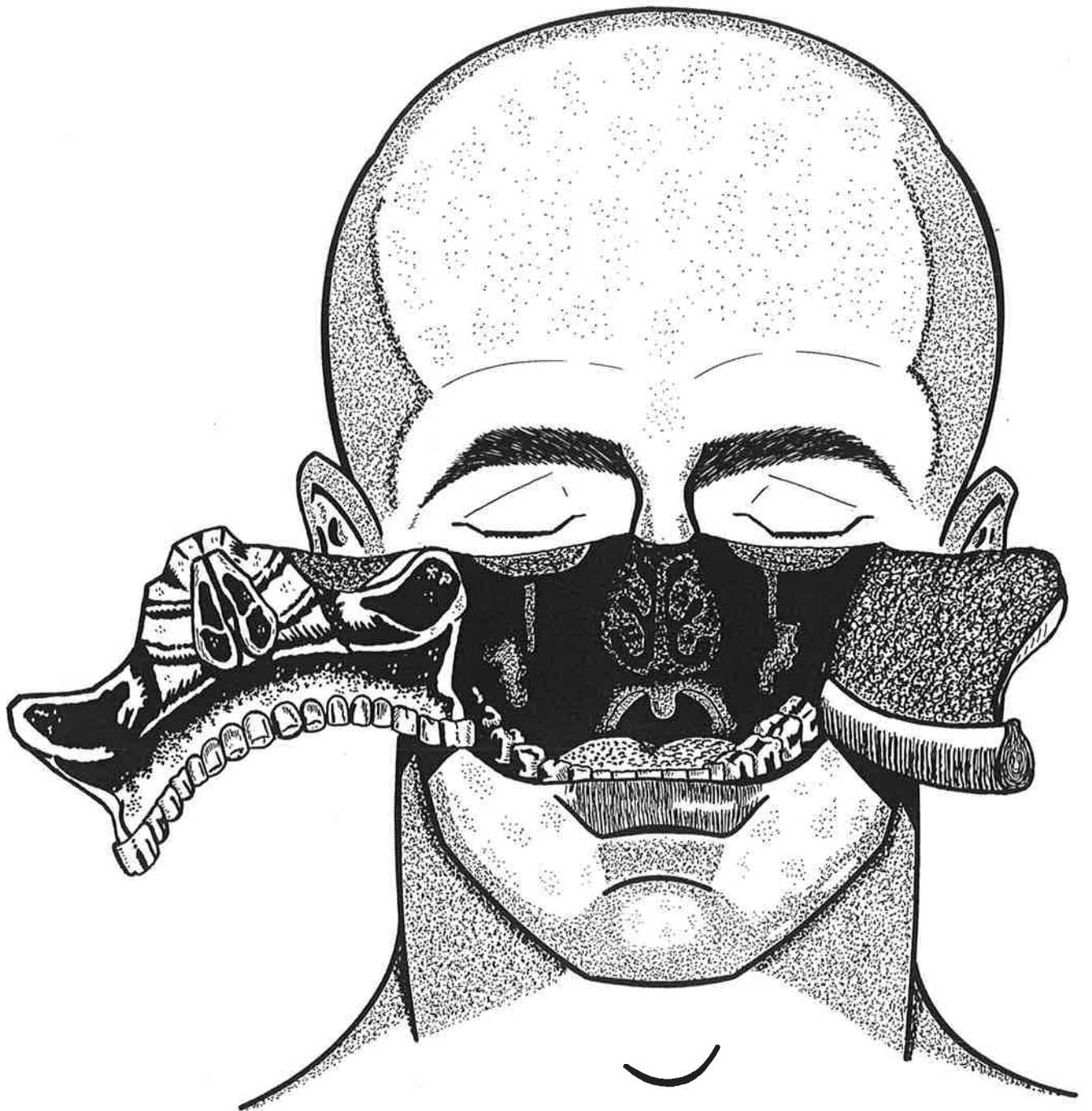


Figura 6

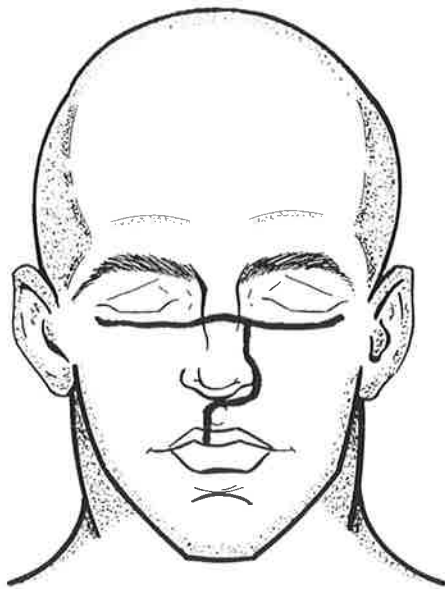


Figura 1

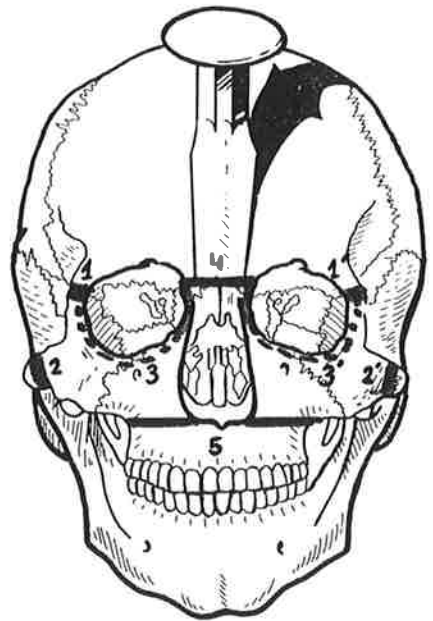


Figura 2

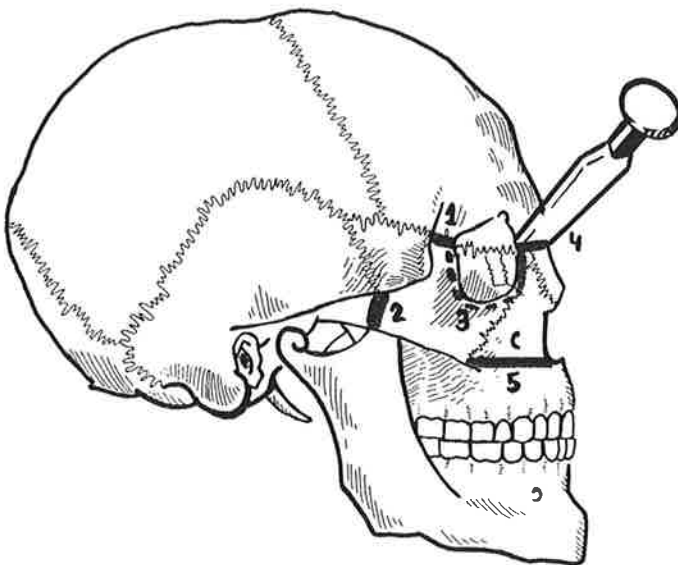


Figura 3

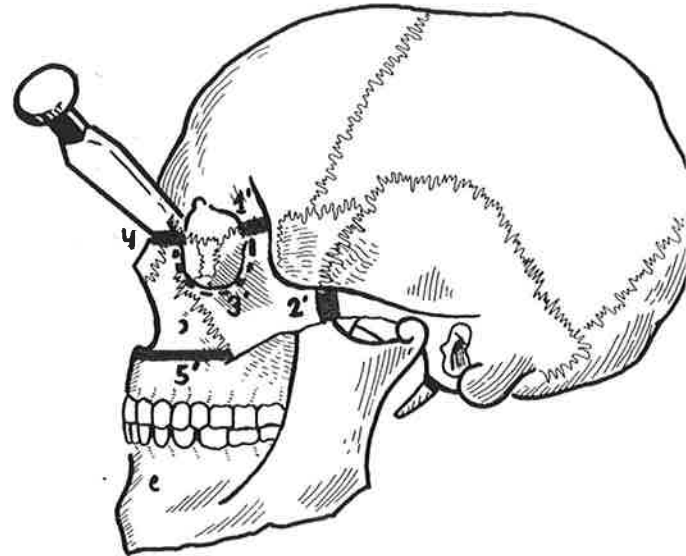


Figura 4

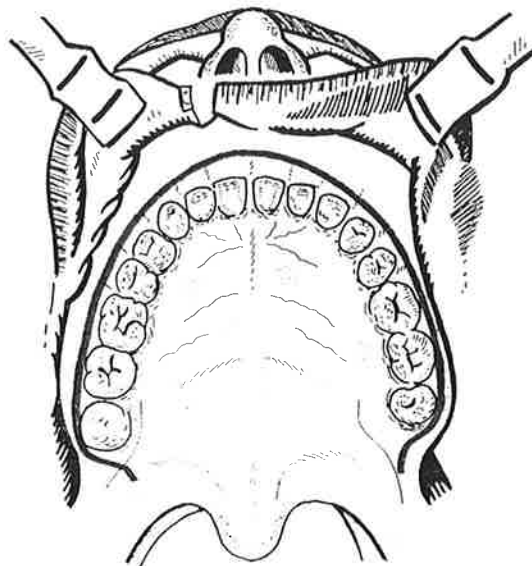


Figura 5

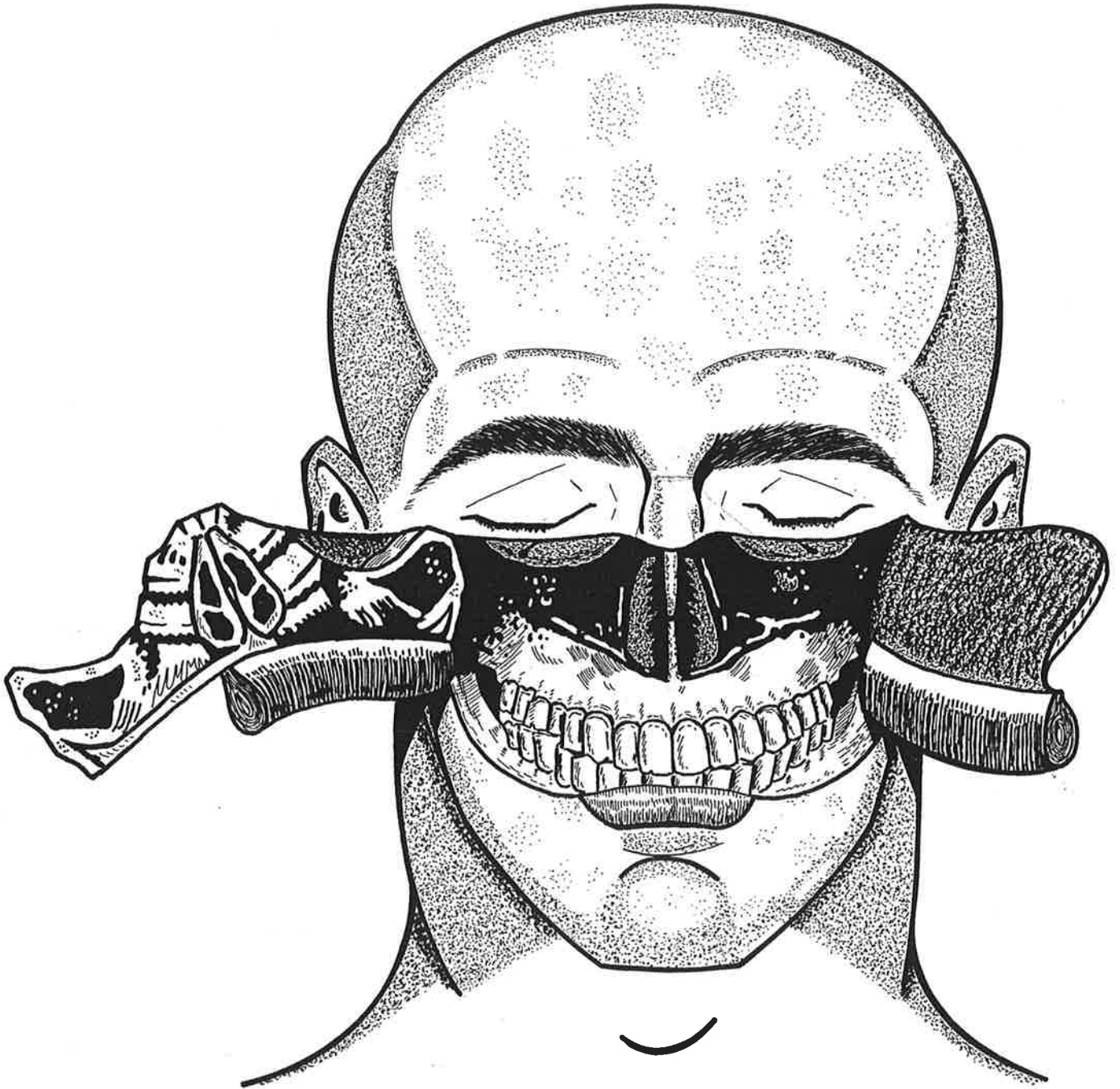


Figura 6