

HOSPITAL "MIGUEL SERVET" OF ZARAGOZA

DEPARTMENT OF ORAL AND MAXILLOFACIAL SURGERY

HEAD OF THE DEPARTMENT

FRANCISCO HERNANDEZ ALTEMIR, M.D.

"CRANIOFACIAL PEDICULATION SURGERY, A NEW METHOD"

FRANCISCO HERNANDEZ ALTEMIR, M.D.

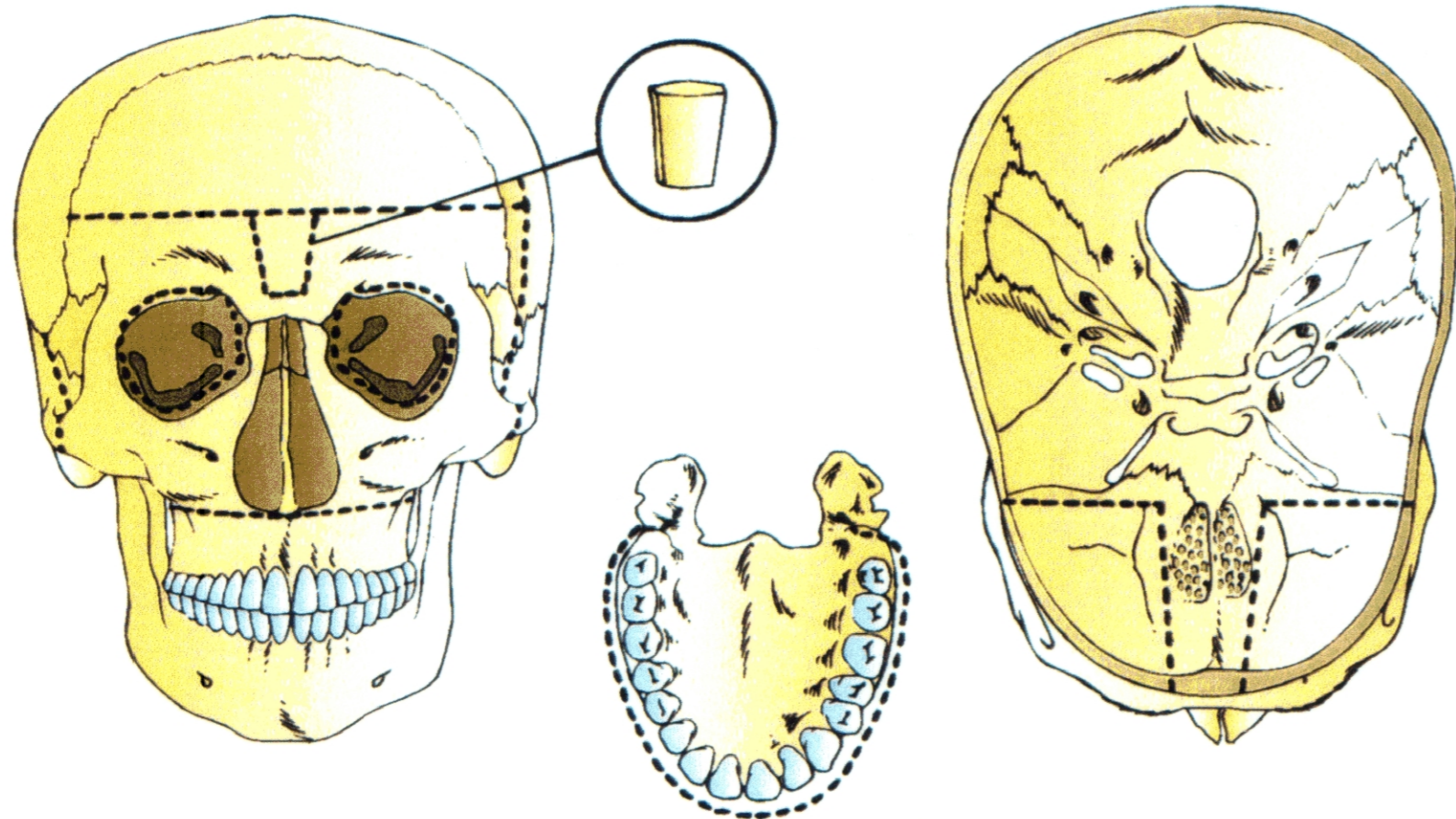


Fig. 1: Lines of osteotomy

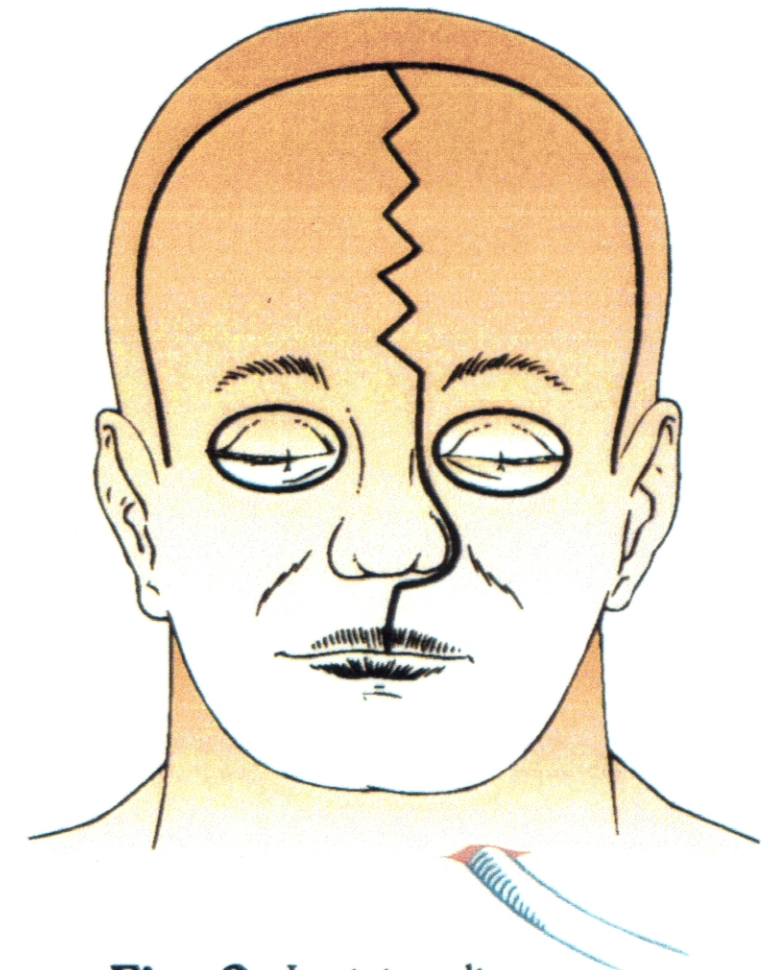


Fig. 2: Incision lines

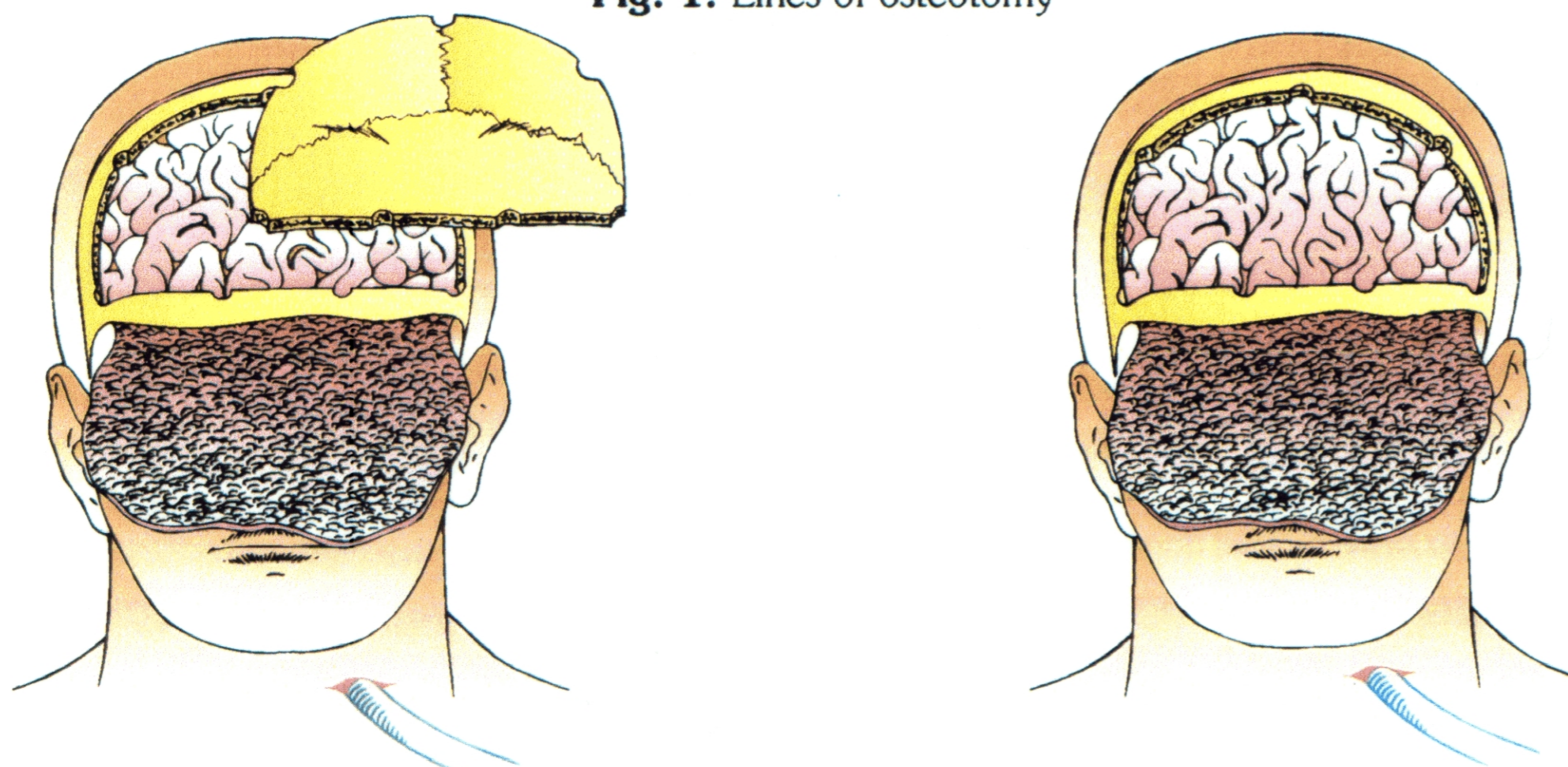


Fig. 3 and 4: Removal of frontal bone

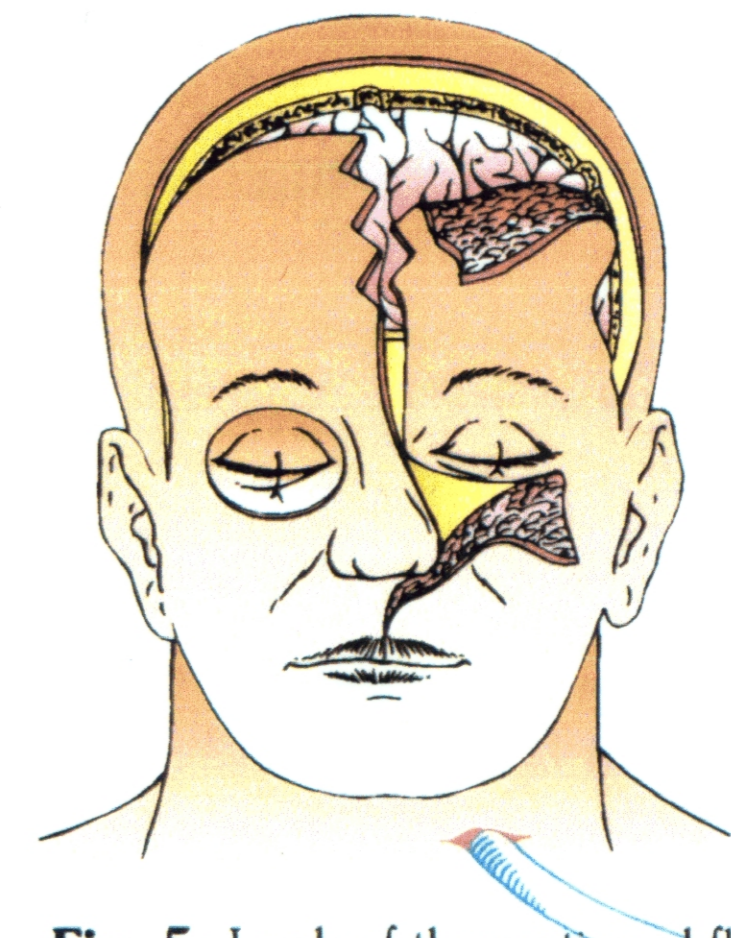


Fig. 5: Look of the sectioned flap

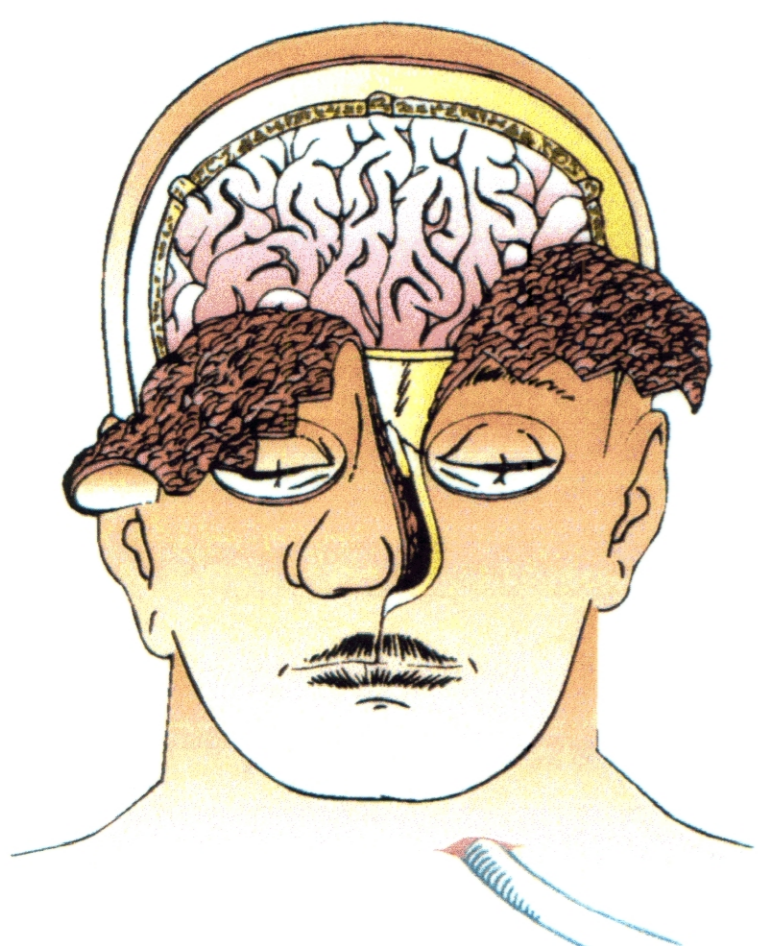


Fig. 6: Start of osteotomy

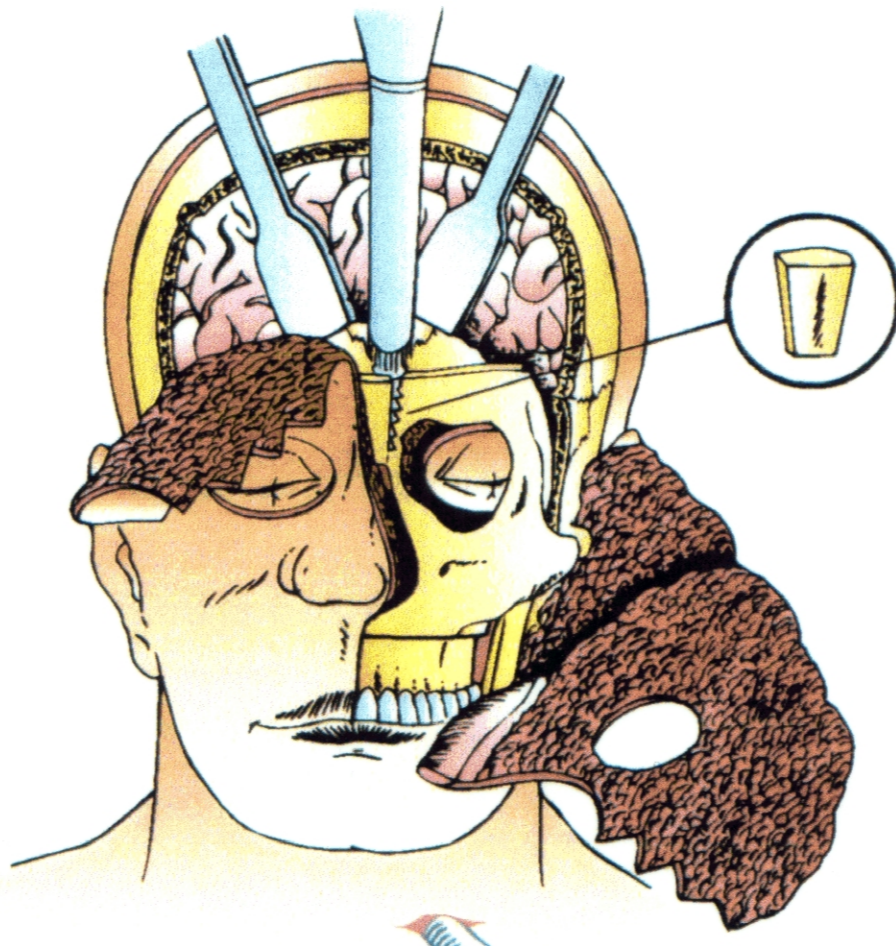


Fig. 7: Beginning craniofacial disjunction

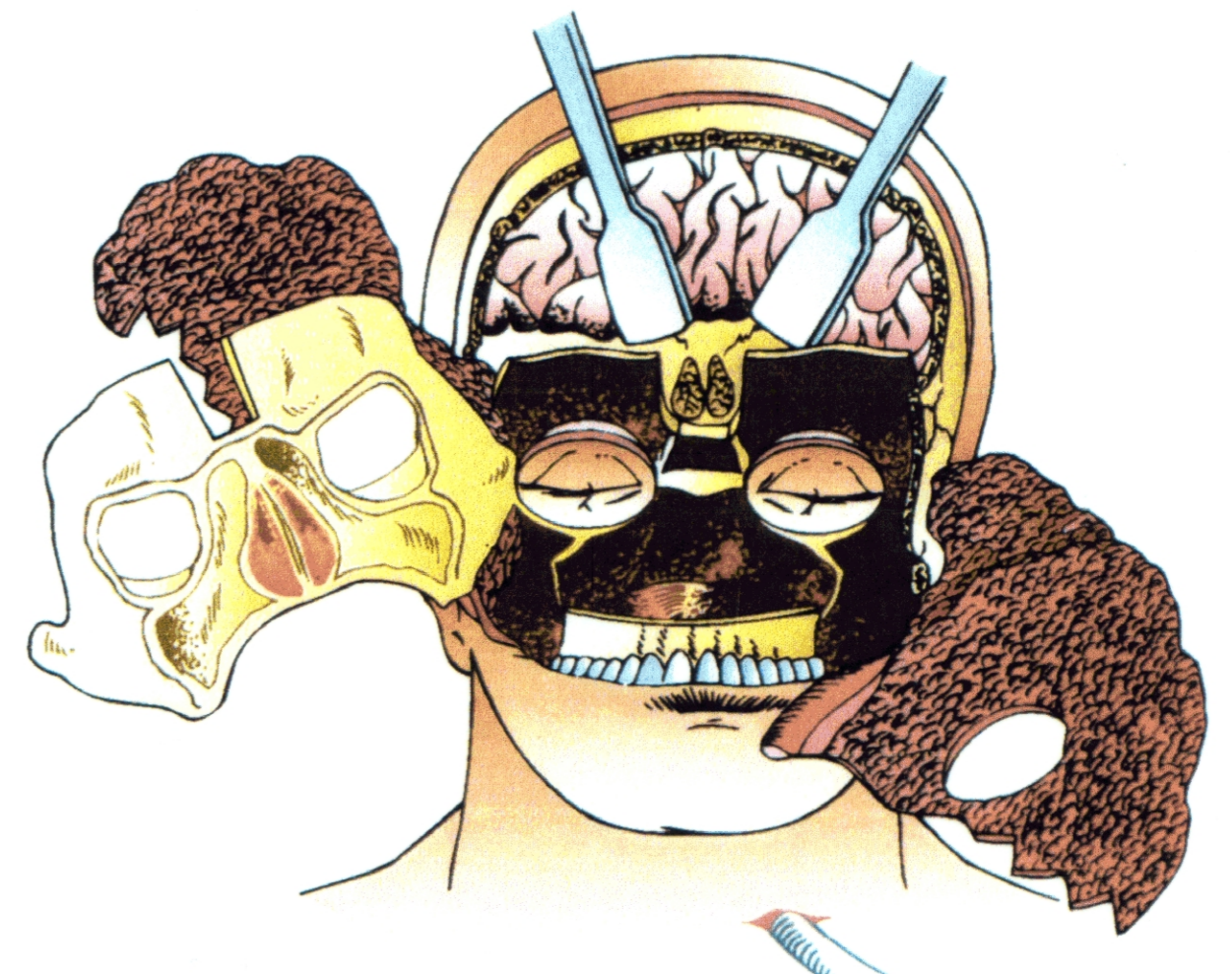


Fig. 8: The whole craniofacial bulk is pedicled

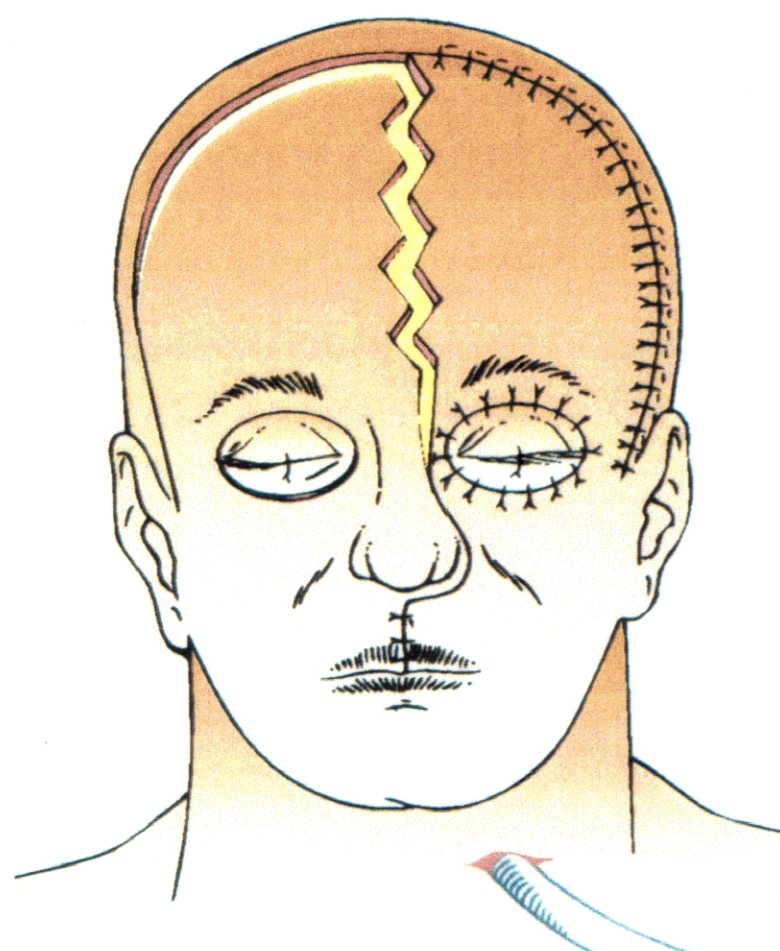


Fig. 9: Beginning of suture

TECHNIQUE OF BILATERAL CRANIOFACIAL PEDICULATION

By means of the technique of craniofacial pediculation it is possible to unite in a more rational way transfacial and craniofacial surgery, avoiding multifracture of craniofacial bones (which is necessary if both are performed separately). Thus, the access is improved and the reconstruction procedures facilitated thanks to a medial craniofacial serrated incision, plus periorbitary incision, uni or bilateral.

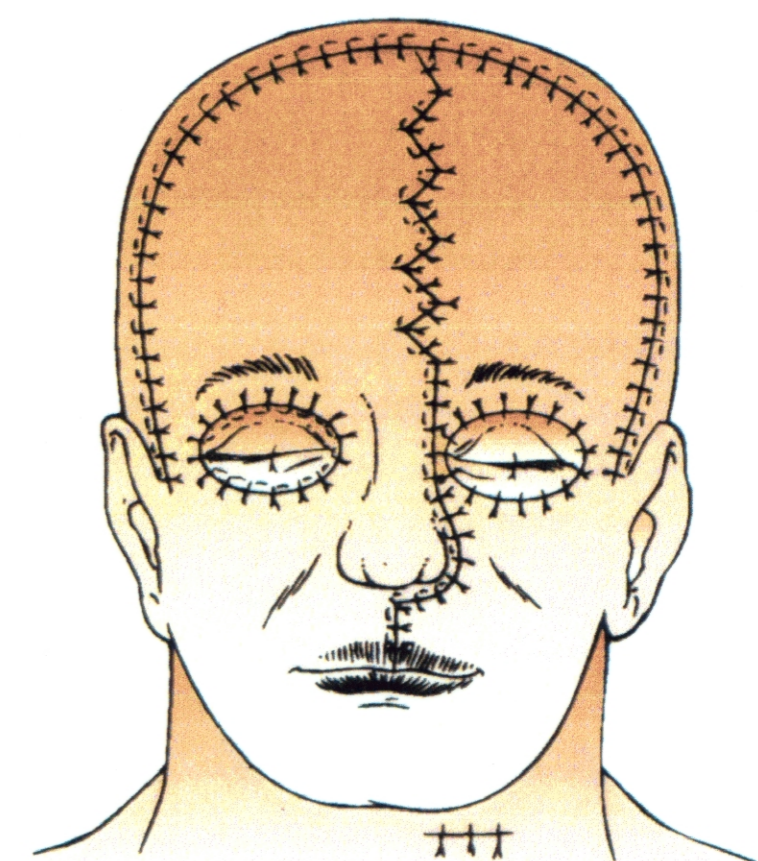


Fig. 10: The suture is completed and the intubation removed

FIRST COMMUNICATION AT: SYMPOSIUM DISMANTLING AND REASSEMBLY OF THE FACIAL SKELETON-STATE OF THE ART-CASTELLANZA (VA)-NOVEMBER 26, 1994.

Under the patronage of the EUROPEAN ASSOCIATION FOR CRANIOMAXILLOFACIAL SURGERY, EUROPEAN SKULL BASE AND ITALIAN SOCIETY FOR MAXILLOFACIAL SURGERY.

ILUSTRE COLEGIO OFICIAL DE ODONTOLOGOS Y ESTOMATOLOGOS DE ARAGON. SYMPOSIUM 24 DE FEBRERO DE 1995 ZARAGOZA

XIII CONGRESO NACIONAL DE LA SOCIEDAD ESPAÑOLA DE CIRUGIA ORAL Y MAXILOFACIAL

PAMPLONA-IRUÑA 29-30-31 MAYO - DONOSTIA-SAN SEBASTIAN 31 MAYO - 1-2-3 JUNIO 1995

THE XIV CONGRESS OF EUROPEAN ASSOCIATION FOR CRANIO-MAXILLOFACIAL SURGERY.

HELSINKI 1-5 SEPTEMBER 1998