

HOSPITAL "MIGUEL SERVET" OF ZARAGOZA

DEPARTMENT OF ORAL AND MAXILLOFACIAL SURGERY

HEAD OF THE DEPARTMENT

FRANCISCO HERNANDEZ ALTEMIR, M.D.

"CRANIOFACIAL TRACTION ARCH A NEW DEVICE"

FRANCISCO HERNANDEZ ALTEMIR, M.D.

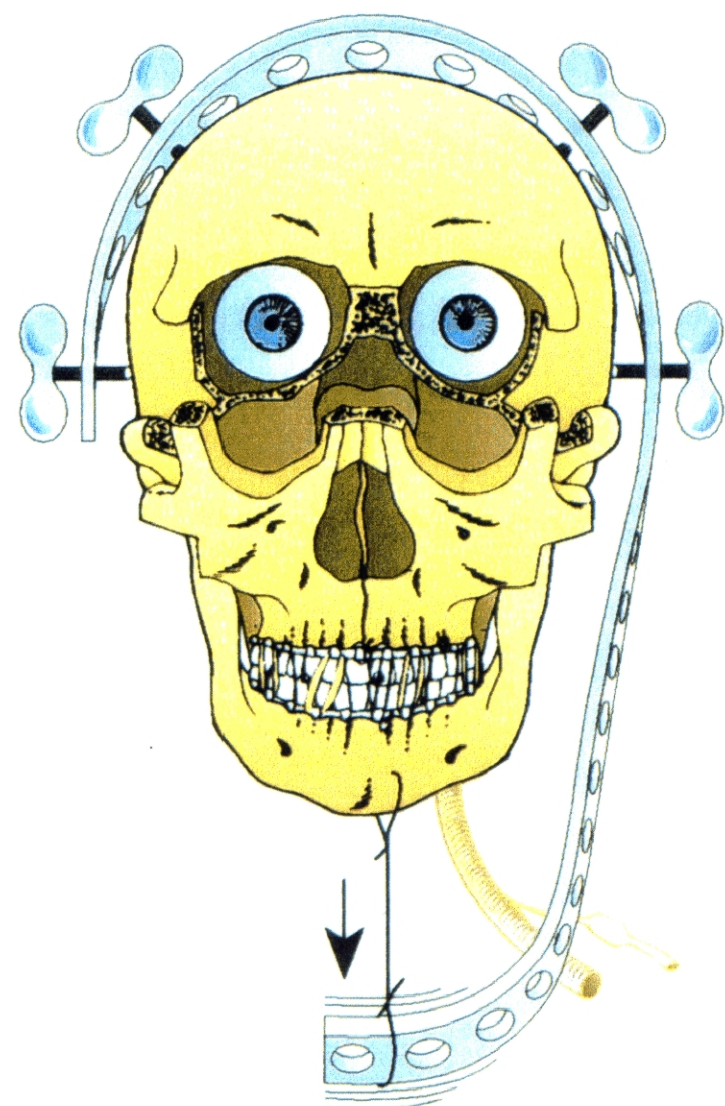


Fig. 1 : The craniofacial arch allowing, by means of the intermaxillary blockade, the traction of the maxillary-mandibular bulk.

CRANIOFACIAL TRACTION ARCH A NEW DEVICE

It is with the aim of facilitating some surgical procedures in the area of oral and craniofacial surgery and making craniomandibular tractions in several congenital or acquired diseases (traumatism, oncological patients, etc.) that we have developed a Craniofacial Traction Arch.

Access into nasal and rhinopharyngeal space and skull base by means of an Osteotomy Le Fort I, making use of the Craniofacial Traction Arch and Submental Intubation.

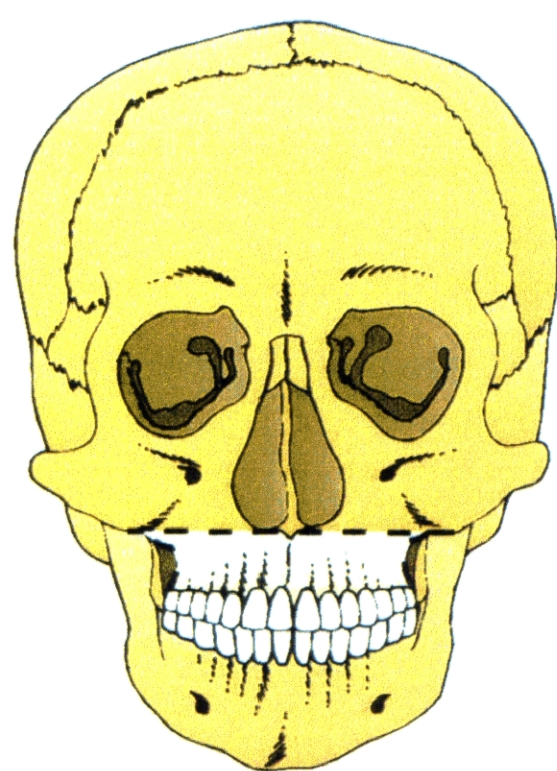


Fig. 1 : Osteotomy of the type Le Fort I

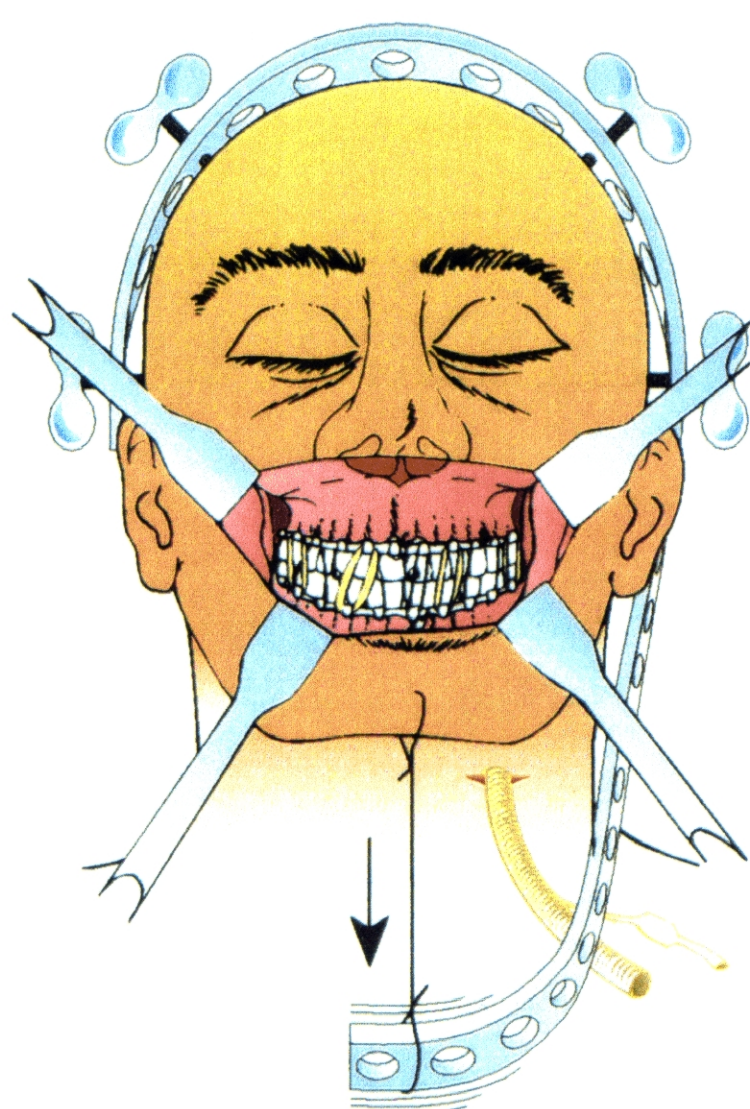


Fig. 2 : The Osteotomy Le Fort I is designed after the submental intubation has been made and the Craniofacial Traction Arch has been attached as well as the intermaxillary blockade, so that it is possible to pull down the maxillary-mandibular bulk from the chin, by means of a wire, or else from the blockade splints, passing the wire by percutaneous way.

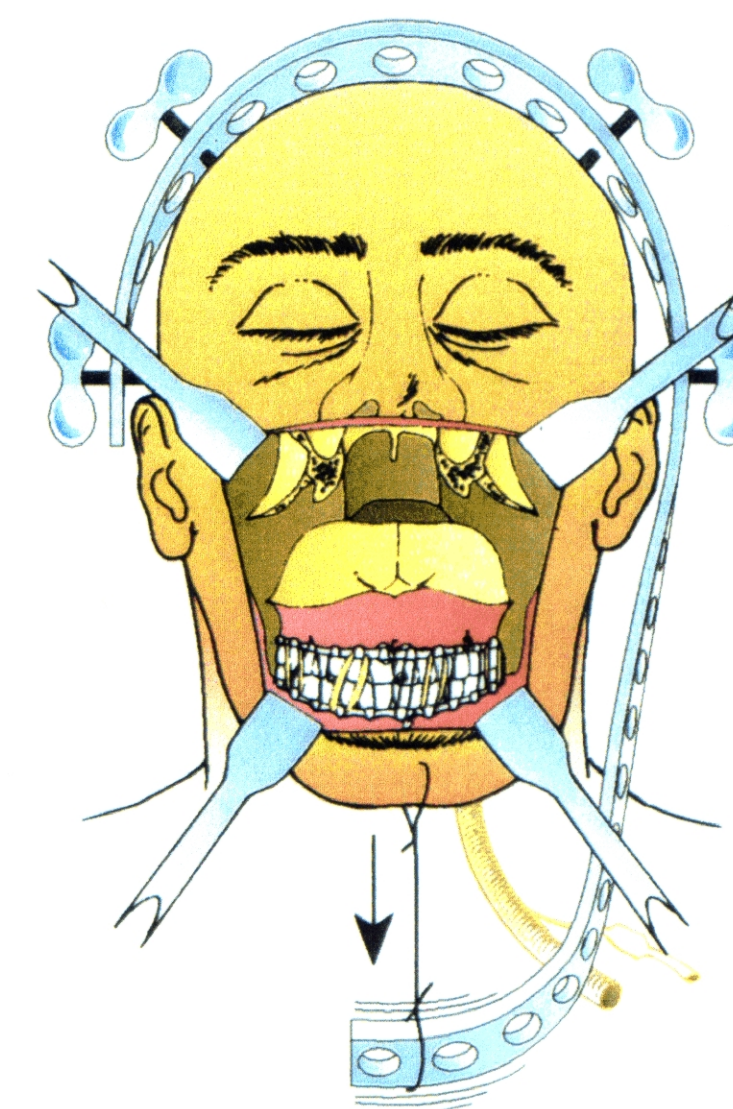


Fig. 3 : It is possible to appreciate the surgical area which is obtained, leaving clear for our work the nose, rhinopharynx, oral cavity and skull base, being absent the disturbance of the anaesthetic tube. In addition, the traction allows a wider movement of the osteotomized jawbone.

Access to the skull base by means of a Le Fort II Osteotomy and the help of the Submental Intubation, intermaxillary blockade and Craniofacial Traction Arch.

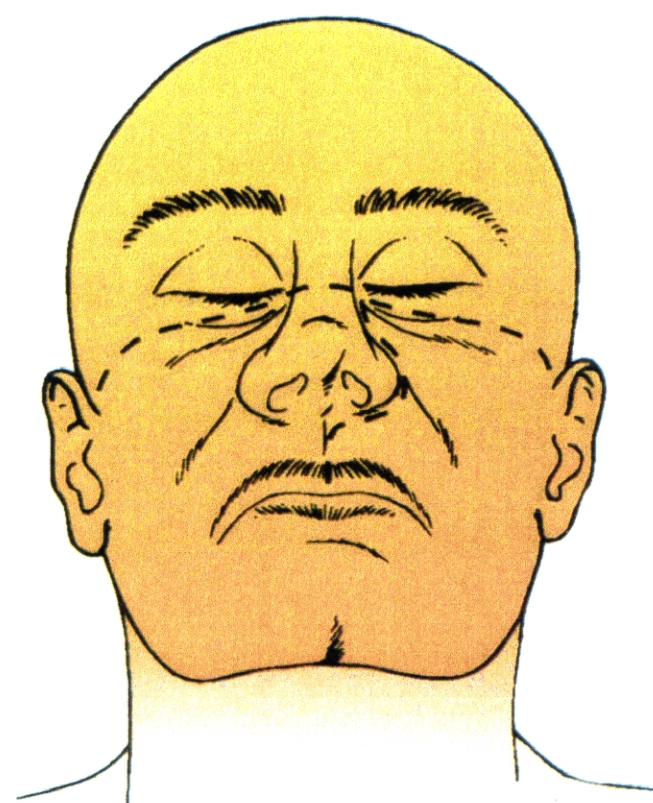


Fig. 1 : Design of the cutaneous incisions. The oral ones are parallel to the labial fraenum and they follow in both sides the gingival border of the end of the vestibulum. The palatine fibromucose is not separated.

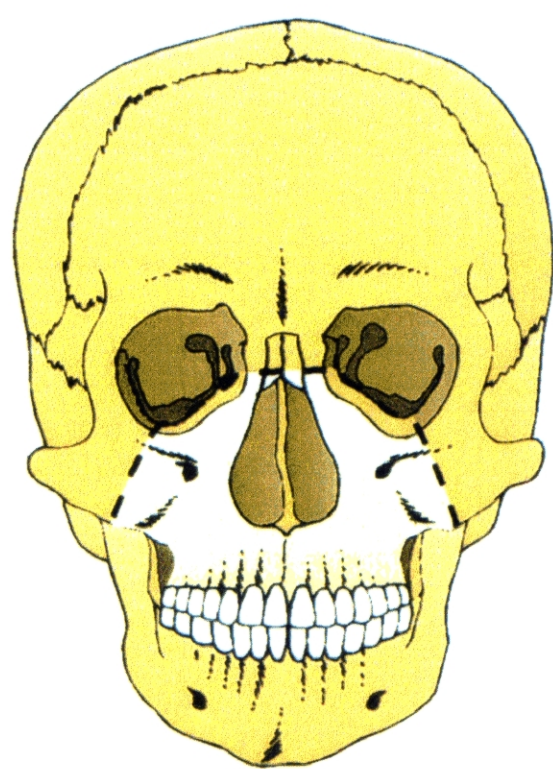


Fig. 2 : Design of osteotomies.

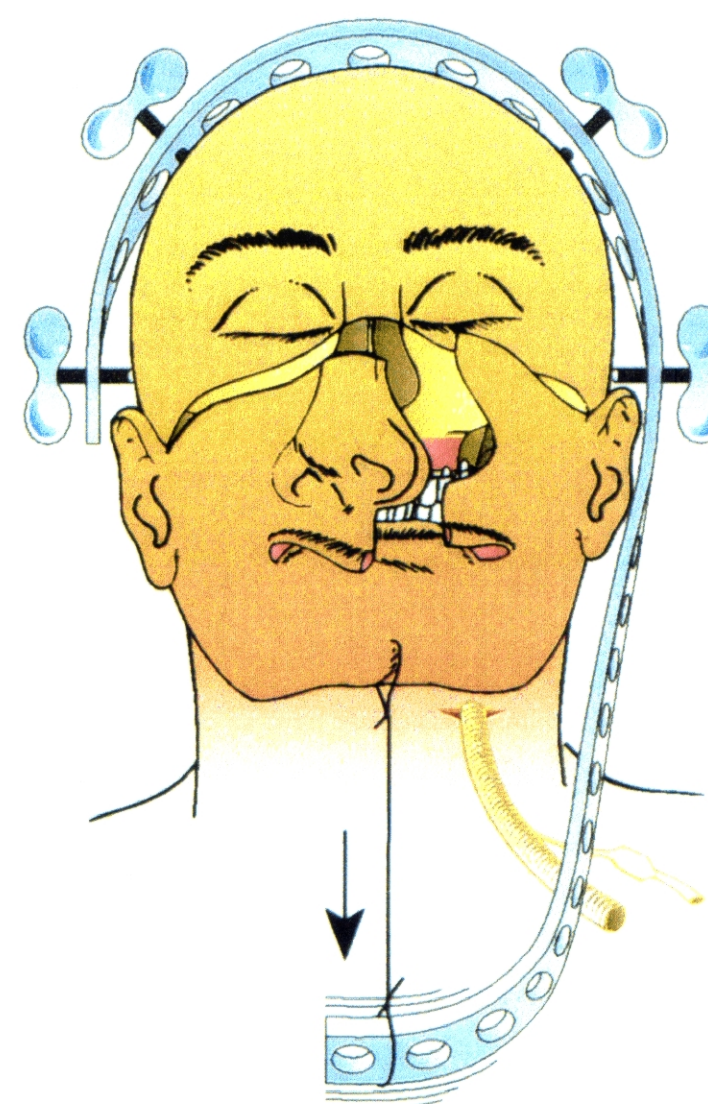


Fig. 3 : Design of our surgical act. There is a main flap which comprehends the nasal pyramid and another one which comprehends paramedial region of the other side. There can also be observed the Submental Intubation, the Craniofacial Traction and the intermaxillary blockade.

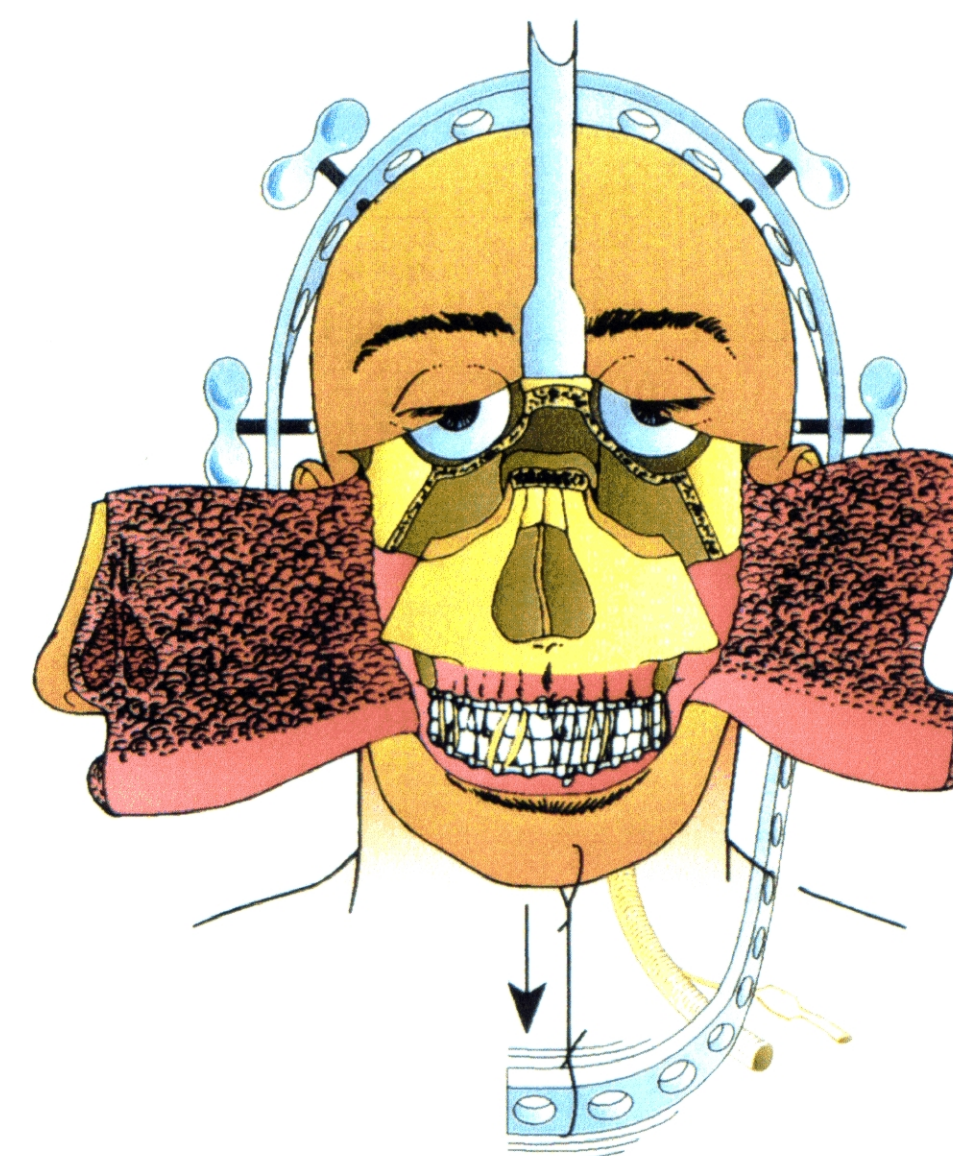


Fig. 4 : Aspect of the surgical area and the subcranial space obtained.

FIRST COMMUNICATION AT: SYMPOSIUM DISMANTLING AND REASSEMBLY OF THE FACIAL SKELETON-STATE OF THE ART-CASTELLANZA (VA)-NOVEMBER 26, 1994.
Under the patronage of the EUROPEAN ASSOCIATION FOR CRANIOMAXILLOFACIAL SURGERY, EUROPEAN SKULL BASE AND ITALIAN SOCIETY FOR MAXILLOFACIAL SURGERY.

XIII CONGRESO NACIONAL DE LA SOCIEDAD ESPAÑOLA DE CIRUGIA ORAL Y MAXILOFACIAL
PAMPLONA-IRUÑA 29-30-31 MAYO - DONOSTIA-SAN SEBASTIAN 31 MAYO - 1-2-3 JUNIO 1995

THE XIV CONGRESS OF EUROPEAN ASSOCIATION FOR CRANIO-MAXILLOFACIAL SURGERY.
HELSINKI 1-5 SEPTEMBER 1998