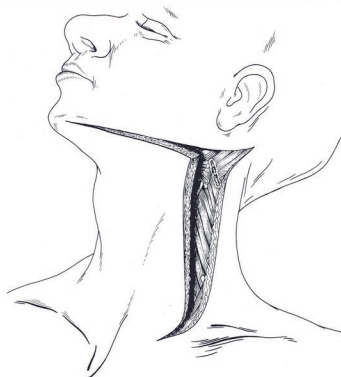


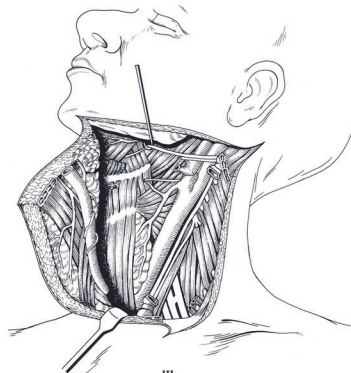
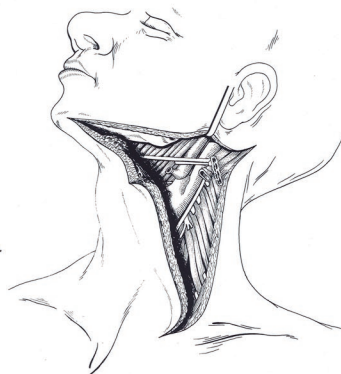
Department of Oral and Maxillofacial Surgery «Miguel Servet Hospital», Zaragoza  
**A MODIFICATION IN THE TECHNIQUE OF THE RADICAL DISSECTION OF THE NECK**

By Dr. F. HERNANDEZ ALTEMIR

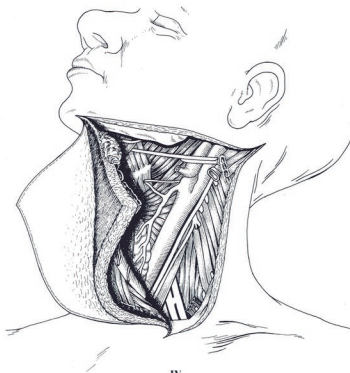
DEPARTMENT HEAD



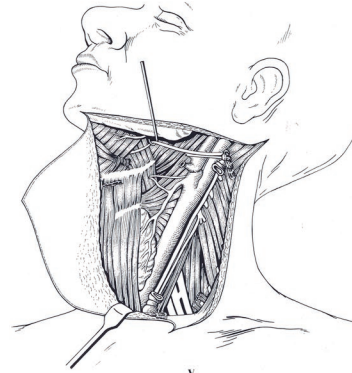
I  
 Incision and beginning of both superior and posterior dissections simultaneously carried out.



III  
 The extirpation bloc which is like splinted by the skin has been separated from the surface plane of the deep cervical fascia.



IV  
 Separation of the skin and cellular tissue over the platysma.



V  
 The anterior portion has been sectioned, it is the final aspect, which is no other but that of a classical radical dissection.

Acknowledgement to Dr. R. Castillo Escandon who cooperated in the first clinical cases.  
 Published in NM Especial Domingo, 25th March 1973, Vol. 1 No. 5.