Trabajos originales
DOCTRINA
E
INVESTIGACION

SERVICIO NACIONAL DE CIRUGIA MAXILO-FACIAL
Jefe del Servicio: Profesor Sada
MADRID

Una nueva técnica, en el tratamiento quirúrgico del prognatismo, por vía intraoral

Dr. HERNANDEZ

De todos es conocida la multiplicidad de métodos intra y extraorales para el tratamiento del prognatismo. Todos ellos adolecen de ventajas e inconvenientes, al igual que el nuestro; pero, tal vez, sea éste el que muestre menos perjuicios para el paciente, que es, al fin y al cabo, quien va a soportar el trauma quirúrgico.

Nuestro método se basa en algunos de los beneficios de los tratamientos intraorales del prognatismo y en las ventajas del tratamiento extraoral, según la técnica de Letterman, con algunas modificaciones.

En honor a la brevedad, no me voy a extender en datos históricos ni en describir técnicas de tratamientos quirúrgicos del prognatismo. Solamente, por justicia, mencionaré los nombres de los autores que con sus técnicas han influido en mi modo de hacer; éstos son Obwegeser y Letterman, fundamentalmente; el primero, porque emplea técnicas intraorales; el segundo, porque emplea, tal vez, una de las osteotomías más lógicas y sencillas; de ambos autores y, sobre todo, de mi formación quirúrgica en el Servicio Nacional de Cirugía Maxilo-Facial, han hecho que surgiera la idea de realizar una "nueva técnica" del tratamiento quirúrgico del prognatismo que aunara las ventajas de las ya experimentadas favorablemente.

En nuestra técnica, y sin detenernos en explicaciones en cuanto a estudios previos al acto quirúrgico, tales como ortopantomografías, telerradiografías, toma de modelos, fotos, etc., procedemos de la siguiente manera, a grandes rasgos:

1.° Paciente bajo anestesia general, con intubación nasotraqueal con manguito traqueal.

2.° Colocación de férulas para bloqueo intermaxilar.

3.° Taponamiento faríngeo.

4.° Cuña intermaxilar.

5.° Infiltración de algún vasoconstrictor (cualquier anestésico vasoconstrictor reconocido en el mercado es bueno, advirtiéndoselo al anestesiólogo) a nivel de la zona a incindir, esto es, en vestíbulo y zona maseterina.

6.° Marcado de la incisión, que va desde la base de la coronoides hasta la altura del primer bicúspide, por el borde anterior de la rama ascendente, pasando a nivel del cuerpo de la mandíbula, en la zona próxima al fondo vestibular donde la fibromucosa se encuentra despegada del hueso y por encima de la inserción de los frenillos hasta la altura indicada.

7.° Despegamiento de abajo arriba, es decir, empezando en el fondo del vestíbulo y rechazando en su totalidad los músculos maseteros y cigomático mandibular y las adherencias del buccinador, con lo que nos queda al descubierto todo el tercio medio y posterior externo del cuerpo de la mandíbula y la totalidad de la cara externa de la rama ascendente.

8.° Colocación de los "elevadores de huesos" que se ven en el esquema u otros similares, calzando el borde posterior de la rama ascendente (fig. 1).

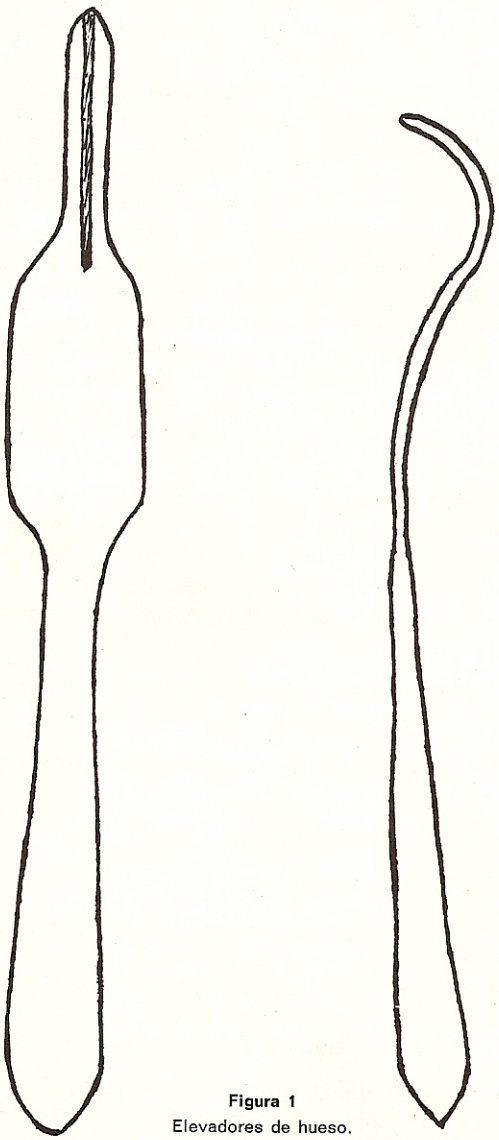

Figura 1
Elevadores de hueso.

9.° Con torno o, mejor, con turbina quirúrgica, procedemos al desgaste de la zona indicada en el dibujo, esto es, el espacio ABCD (figura 2).

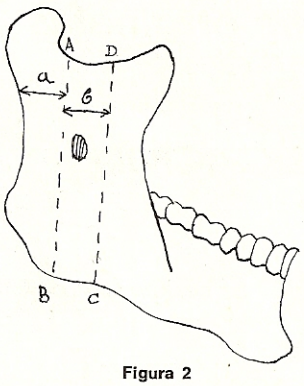

Figura 2
AB=Línea de osteotomía, en bisel favorable al desplazamiento anterolateral del fragmento posterior de osteotomía.

ABCD=Zona que debe ser desgastada a fresa a fin de "reavivar" el área, para facilitar la unión de los fragmentos óseos y que en su borde AB deja un bisel similar y opuesto al anterior.

10.° Con la sierra microoscilante hacemos el marcado profundo de la osteotomía vertical a realizar que, siendo paralela al borde posterior de la mandíbula, pasa inmediatamente por detrás del agujero de entrada del conducto dentario y tiene una trayectoria que va desde la escotadura sigmoidea a la tuberosidad de inserción pterigoidea, y que deja en el hueso mandibular una huella de bisel, favorable al desplazamiento posteroanterior del fragmento posterior de la osteotomía realizada (fig. 3). La sección completa puede ayudarse con escoplo; realizado esto, se despegan las fibras del pterigoideo interno que puedan quedar adheridas a dicho fragmento y se pasa al otro lado, realizando el mismo proceder. Se retira el taponamiento faríngeo. Hecho esto, se lleva a su lugar ideal la oclusión y se comprueba la posición que adoptan los fragmentos osteotomizados, a fin de "retocar" las zonas óseas que puedan interferir en su ensamblaje. A conti-

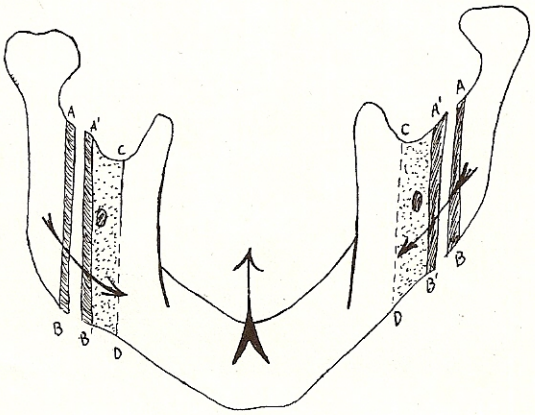

Figura 3

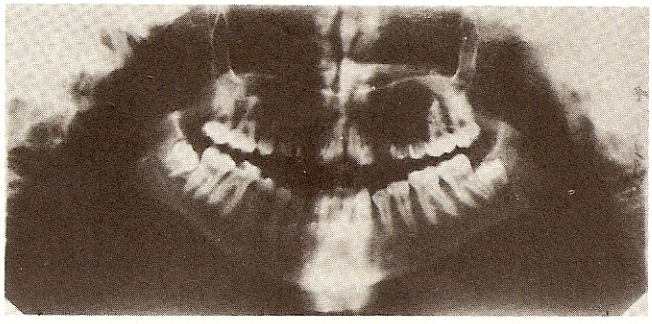

Caso 1: Preoperatorio.

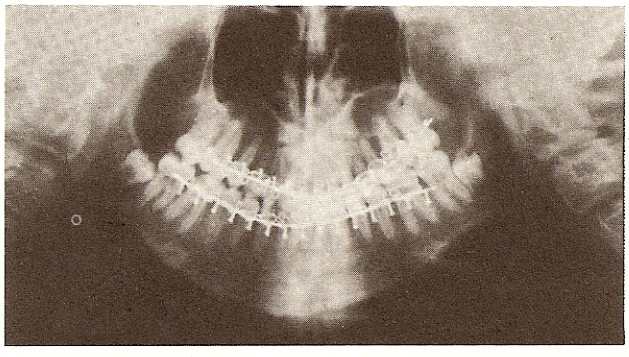

Caso 1: Postoperatorio.

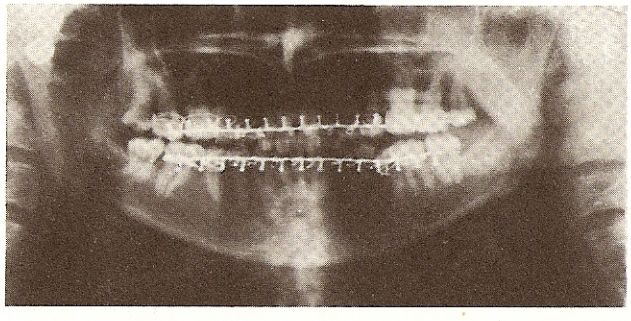

Caso 2: Postoperatorio (se ven las líneas verticales de osteotomía).

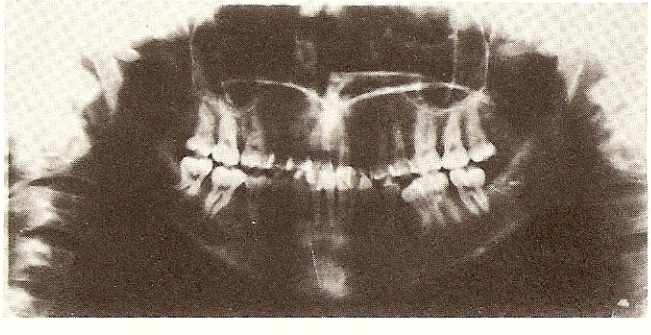

Caso 2: Resultado final.

Caso 1: Prognatismo.

Caso 1: Vista lateral.

Caso 1: Paciente intervenida.

Caso 1: Paciente intervenida.

Caso 2: Prognatismo con laterodesviación.

Caso 2: Vista de perfil.

Caso 2: Postoperatorio.



Caso 2: Perfil postoperatorio.

nuación se sutura con seda la fibromucosa, dejando un drenaje intraoral de tejadillo o extraoral, con aspiración continua, tipo Redon, bilateral.

Por fin, se fija definitivamente el bloqueo intermaxilar, que se mantendrá unos 45 ó 50 días, con controles radiológicos de tipo ortopantomográfico, a los 4 ó 6 días de la intervención, a los 25 ó 30 días y previamente a la retirada del bloqueo.

Esta técnica ha surgido de la necesidad de racionalizar algo más el tratamiento quirúrgico de la mayoría de los prognatismos y creemos que las ventajas más a tener en cuenta son:

1.º Ausencia de cicatriz extraoral.

2.º Imposibilidad de lesionar el ramus marginalis del facial.

3.º Imposibilidad de fístulas salivares parotídeas que, aunque temporales y raras, no dejan de ser probables en la técnica extraoral, al interferir sobre la cola de la parótida.

4.º No necesidad de despegamiento de la cara faríngea mandibular, con el riesgo consiguiente de lesiones del paquete vasculonervioso mandibular y la disminución o ausencia de edema laterofaríngeo, con los inconvenientes que esto lleva consigo.

5.º Los tejidos paraparotídeos, fundamentalmente, son menos traumatizados por este método.

6.º La ejecución, con instrumental adecuado y con suficiente preparación quirúrgica, es más fácil que en el resto de los procedimientos descritos, abreviándose notablemente el tiempo de la intervención.

7.º El procedimiento es igualmente válido para la corrección de ciertas laterodesviaciones mandibulares.

La idea de la técnica ha surgido de una manera rápida, pero buscada; su sistematización, en cambio, es fruto de una labor de equipo y de una experiencia que ya se va haciendo dilatada en los diferentes aspectos de la cirugía maxilo-facial. Hemos escrito con "estilo quirúrgico", con lo que el trabajo no deja de ser más que una caricatura del acto quirúrgico, para que los que lo lean no pierdan la idea o el concepto de la técnica, que pudiera quedar enmascarada si nos metemos en detalles o retoques que todo cirujano con cierta experiencia será capaz de introducir. Nunca dos cirujanos operan igual, pero, en cambio, sí pueden pensar de modo muy similar.

En el momento de publicarse este trabajo tenemos realizados tres casos, con excelente resultado en los tres. Presentamos a continuación dos casos, antes y después.

Nota del autor.—En el "Oral Surgery" de marzo de 1971 aparece descrita una técnica similar a la nuestra, de cuya existencia no teníamos noticia alguna cuando realizamos nuestros primeros casos; ello nos ha animado, no obstante, a publicarla, tal y como la concebimos y como técnica propia.

El trabajo que sigue: "The Stability of intraoral Vertical Ramus Osteotomy and Factors Related to Skeletal Relapse" publicado recientemente en Aesth Plast Surg (2011) 35:192-197, parece que EVIDENCIA Y CONFIRMA, aun más, lo reseñado cuando publicamos en Medicamenta Año XXX Madrid 15 de abril de 1972. Num 498 Tomo LIX 287-292, el nuestro titulado: "Una nueva técnica, en el tratamiento quirúrgico del prognatismo, por vía intraoral", que quizás puede ayudar a reflexionar, para no dejar de practicar nuestra técnica intraoral, frente a otras más habituales . Dr. F. Hernández Altemir

Aesth Plast Surg (2011) 35:192–197
DOI 10.1007/s00266-010-9582-y

ORIGINAL ARTICLE

The Stability of Intraoral Vertical Ramus Osteotomy and Factors Related to Skeletal Relapse

Chun-Ming Chen · Steven Sheng-Tsung Lai · Chau-Hsiang Wang · Ju-Hui Wu · Kun-Tsung Lee · Huey-Er Lee

Received: 30 April 2010 / Accepted: 19 August 2010 / Published online: 25 September 2010

Abstract
Background Intraoral vertical ramus osteotomy (IVRO) and sagittal split ramus osteotomy (SSRO) have been advocated as two major procedures for the correction of mandibular prognathism. However, only a few reports with at least a 2-year follow-up period describe the long-term stability especially of the IVRO method. This study aimed to identify factors contributing to skeletal relapse after a 2-year postoperative follow-up period.
Methods A set of three standardized lateral cephalograms were obtained from each subject, taken preoperatively (T1), immediately postoperatively (T2), and 2 years postoperatively (T3). Relapse was defined as forward movement of the menton (Me) after a 2-year follow-up period. Two angular measurements (SNB and SN-occlusal plane angle) and five linear measurements (horizontal Me, vertical Me, overbite, anterior facial height, and mandibular length) were compared immediately after the operation and at the 2-year follow-up visit.
Results The mean setback of the menton was 12.8 mm, and the mean relapse was 1.3 mm (10.2% = 1.3/12.8). The magnitude of the setback was not significantly accounted for in the relapse. There were weak correlations between the relapse and the concerned factors, namely, overbite, anterior facial height, mandibular length SNB, and SN-occlusal plane angle).
Conclusion The current study confirmed the stability of IVRO in the treatment of mandibular prognathism.

Keywords Intraoral vertical ramus osteotomy · Mandibular prognathism · Sagittal split ramus osteotomy · Skeletal stability

C.-M. Chen · S. S.-T. Lai
Department of Oral and Maxillofacial Surgery, Kaohsiung Medical University Hospital, Kaohsiung Medical University, No. 100, Shih-Chuan 1st Road, Kaohsiung, Taiwan

C.-H. Wang · H.-E. Lee (✉)
Graduate Institutes of Dental Sciences, College of Dental Medicine, Kaohsiung Medical University, No. 100, Shih-Chuan 1st Road, Kaohsiung, Taiwan
e-mail: komschen@yahoo.com.tw

J.-H. Wu · K.-T. Lee
Department of Family Dentistry, Kaohsiung Medical University Hospital, Kaohsiung Medical University, No. 100, Shih-Chuan 1st Road, Kaohsiung, Taiwan

Prognathism is used to describe relationship between the maxillary and mandibular arches. Mandibular prognathism is a potentially disfiguring profile in which the mandible outgrows the maxilla, resulting in a protrusive chin. Mandibular prognathism presents the Angle class III malocclusion with a reverse overjet.

Emrich et al. [1] proceeded with an epidemiologic study on the prevalence of malocclusions. They found a 1% prevalence of class III malocclusions for both 6- to 8-year-olds and 12- to 14-year-olds in the 7,654 children they examined.

A relatively high prevalence of class III malocclusion has been detected in the Asian population. Lew et al. [2] reported that the prevalence of class III malocclusion is approximately 12% in the Chinese population.

Mandibular prognathism not only is considered a profile disorder. It also affects the masticatory function. Mastication is an important function of the digestive system. Therefore, masticatory impairment has an impact on the maintenance of good health. These two disorders are the two primary reasons for the treatment of mandibular prognathism.

The most common treatment for mandibular prognathism is a combination of orthodontics and orthognathic surgery. Two main surgical techniques are used to treat mandibular prognathism, namely, sagittal split ramus osteotomy (SSRO) and intraoral vertical ramus osteotomy (IVRO). The most important advantage of IVRO over SSRO is the lower incidence of injury to the inferior alveolar nerve [3, 4]. Therefore, we prefer using IVRO in the treatment of mandibular prognathism. This study aimed to investigate the stability of IVRO and also to explore the factors contributing to relapse.

Materials and Methods

From 1991 to 1998, 25 patients with mandibular prognathism were treated with IVRO at the Oral and Maxillofacial Department of the Kaohsiung Medical University Hospital. All the patients were in the age range of 17 to 29 years (mean, 20.4 years). The IVRO procedure was performed by modified vertical ramus osteotomy [5].

The inclusion criteria specified patients who had mandibular prognathism with natural dentition, no craniofacial anomalies or mandibular asymmetry, no history of trauma or recognized syndromes, no facial growth at the time of operation as verified by serial cephalometric records and measurement, a history of pre- and postoperative orthodontic treatments, operations performed by a single surgeon as a one-jaw procedure, and no fixation between the proximal and distal segments.

Postoperatively, an interocclusal resin splint and intermaxillary fixation were maintained for a minimum of 6 weeks. The orthodontist took about 12 months to complete the postoperative orthodontic treatment. The mean follow-up period was 33.9 months (range, 24–82 months).

Cephalometric radiographs were obtained preoperatively (T1), immediately after surgery (T2), and at least 2 years postoperatively (T3). The following points were identified: sella (S), nasion (N), menton (Me), supramentale (B), pogonion (Pog), articular (Ar), incisor superior (Is), and incisor inferior (Ii). For analysis, x and y coordinate axes were constructed. This coordinate system had its origin at point N and its *x*-axis formed at an angle of 7° upward, with the reference line (NS) as the horizontal axis [6] (Fig. 1). The vertical line was perpendicular to it through the sella as the vertical axis (y-axis).

The parameters related to the angular and linear cephalometric measurements were identified to evaluate the mandibular position as follows:

1. SNB angle: angle between the SN line and the NB line
2. SN-occlusal plane angle: angle between the SN line and the occlusal plane

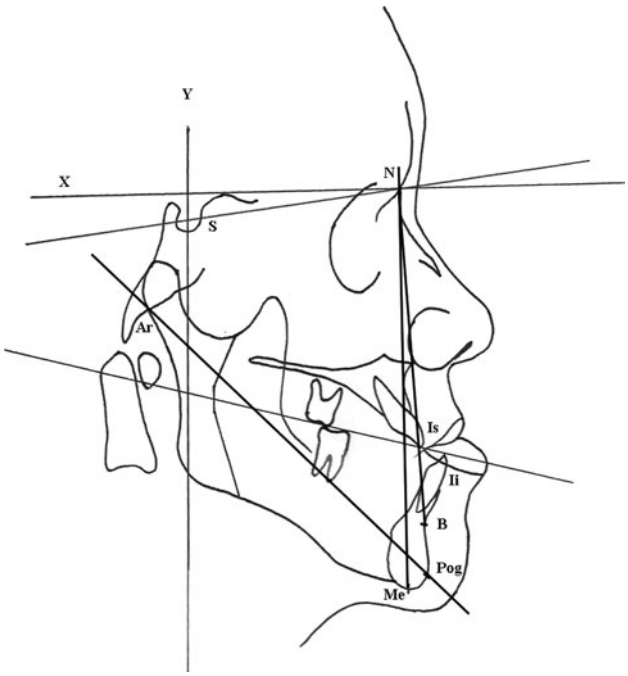

Fig. 1 Cephalometric linear and angular measurements. Reference lines (*x*-axis) are constructed by drawing a line through the nasion 7° up from the S-N line. The *y*-axis is constructed by drawing a line through the sella (S) perpendicular to the *x* axis. The two angular measurements are (1) the SNB angle and (2) the SN-occlusal plane angle. The five linear measurements are (1) the overbite, (2) the anterior facial height (N-Me), (3) the mandibular length (Ar-Pog), (4) the Me length: perpendicular distance from Me to the *y*-axis, and (5) the Me height: perpendicular distance from Me to the *x*-axis

3. Overbite: vertical distance between Is and Ii
4. Anterior facial height (AFH): distance between N and Me
5. Mandibular length (Md-Lth): distance between Ar and Pog
6. Me length: perpendicular distance from Me to the *y*-axis
7. Me height: perpendicular distance from Me to the *x*-axis.

Intrarater error was tested in locating cephalometric landmarks on tracing paper. These serial cephalograms had been recognized twice, and if the difference between the two values of any point or angle exceeded 0.5 or 1 mm, respectively, the point or angle was registered a third time. The third registration was in contrast with the others. The mean value was taken from the two closest values and the outlier was discarded.

The drawing of postoperative prediction is shown in Fig. 2. The pre- and postoperative cephalograms are shown in the Figs. 3 and 4. The reference points and lines were identified on the cephalograms. Positional changes in the landmarks were noted relative to this coordinate system. Relapse was defined as forward displacement of the

Fig. 2 In the case of setback, the inferior portion of the proximal segment (*shaded area*) was excised and trimmed

Fig. 3 The preoperative cephalogram

menton. The variables (overbite-T31, AFH-T31, Md-Lth-T31, SNB-T31, SN-Occl-T31), surgical changes (T21), and 2 years of stability (T32) were calculated and analyzed by

Fig. 4 The postoperative cephalogram

the paired *t* test. Pearson's correlation coefficient was used to detect the correlations between the cephalometric parameters. A *p* value of 0.05 or less was considered significant.

Results

The immediate surgical changes in Me were 12.8 mm in the horizontal direction and 0.9 mm downward in the vertical direction (Table 1). For the 2-year postsurgical changes (T31), Me was 11.5 mm in the horizontal direction and 0.2 mm in the vertical direction. Significant differences between the measurements of time intervals (T1, T2, T3) are shown in Table 2. Significant relapse (T32) was noted, with a 1.3-mm forward movement in the horizontal direction. The overbite values were highly significant in the surgical changes of T21, T32, and T31. The anterior facial height (AFH) and mandibular length (Md-Lth) were stable at the 2-year postsurgical follow-up evaluation (T32). Investigation of the SNB and SN-Occl angles showed that they also were not significant at the 2-year postsurgical follow-up evaluation (T32).

Table 2 shows the Pearson correlation coefficients and their significance values calculated between Me (T32) and the changes in all the variables. Weak correlations were established between the Me (T32) and the change in overbite (T31), the change in AFH (T31), the change in mandibular length (T31), the change in SNB (T31), and the change in the SN-Occl angle (T31). A relationship between the amount of setback (Me-T21) and forward relapse

Table 1 Values for the various cephalometric parameters of the surgical changes (T21) and stability 2 years postoperatively (T32)

Variable	Mean	SD	*p* Value
Horizontal (mm)			
Me-T21	−12.8	3.3	<0.001[a]
Me-T32	1.3	2.4	<0.05[b]
Me-T31 (mm)	−11.5	3.6	<0.001[a]
Vertical (mm)			
Me-T21	0.9	1.8	<0.05[b]
Me-T32	−0.6	1.7	NS
Me-T31	0.2	1.5	NS
Overbite (mm)			
T21	1.5	1.8	<0.001[a]
T32	1.0	1.7	<0.001[a]
T31	2.5	1.6	<0.001[a]
AFH (mm)			
T21	1.0	1.9	<0.05[b]
T32	−1.8	5.0	NS
T31	−0.7	4.7	NS
Md-Lth (mm)			
T21	−8.9	2.8	NS
T32	0.0	2.3	NS
T31	−8.9	2.2	<0.001[a]
SNB (degree)			
T21	−6.4	1.9	NS
T32	0.4	1.3	NS
T31	−6.0	1.7	<0.001[a]
SN-Occl (degree)			
T21	1.3	4.5	NS
T32	0.8	3.5	NS
T31	2.0	4.3	<0.05[b]

SD standard deviation, *Me* menton, *T21* immediate surgical changes, *T32* 2 years of stability, *T31* 2 years of surgical changes, *AFH* anterior facial height, *Md-Lth* mandibular length, *SNB* plane angle, *SN-Occl* plane angle, *NS* not significant ($p > 0.05$)

[a] Highly significant

[b] Significant

Table 2 Relationship between relapse (horizontal Me-T32) and various cephalometric parameters of skeletal changes

Variable	Horizontal Me-T32	*p* Value
Horizontal		
Me-T21 (mm)	−0.2561	
Me-T32 (mm)	–	
Vertical		
Me-T21 (mm)	0.1604	
Me-T32 (mm)	−0.4010	<0.05[a]
Overbite-T31 (mm)	−0.0649	
AFH-T31 (mm)	−0.2731	
Md-Lth-T31 (mm)	0.1690	
SNB-T31 (degree)	0.2758	
SN-Occl-T31 (degree)	−0.0440	

Me menton, *T21* immediate surgical changes, *T32* 2 years of stability, *T31* 2 years of surgical changes, *AFH* anterior facial height, *Md-Lth* mandibular length, *SNB* plane angle, *SN-Occl* plane angle

[a] Significant, Pearson correlation coefficient

(Me-T32) would be expected, but none was found. Even Me (T32) showed a significant change in the vertical direction, but its value (0.6 mm, upward) was too small to have meaning in the clinical analysis.

Discussion

Cephalometric analysis plays a key role in research on the stability of orthognathic surgery. Identifying cephalometric landmarks precisely and consistently is important in evaluation of the outcomes for orthognathic treatment. Dental relapse has been evaluated in molar occlusion and anterior overjet [7]. However, dental relapse can be altered by orthodontic treatment after surgery. It can misinterpret the real relapse of the mandible. Therefore, dental relapse cannot represent the postoperative stability of the mandibular corpus. Reproducible landmarks must be considered as positional changes that can be altered during surgery or bone remodeling over time. Points Pog, B, Gn, and Me are more reproducible and preferred as landmarks in research on the outcomes of orthognathic surgery.

Reviewing the studies of SSRO [8–13], the mean setback ranged from 4.8 to 8.4 mm. These studies showed a tendency for relapse, with the mean amount ranging from 0.6 to 2.87 mm. The relapse was 7.1 to 51.4 percentage of surgical setback. Comparing the amount of setback, the one in our report (12.8 mm) is shown to be greater than in the previous studies. Even in the other studies [8, 13, 14] of IVRO, the mean setback ranged only from 6.3 to 7.5 mm.

From the studies of SSRO, we found that a majority of the maxillofacial changes occurred within 1 year postoperatively. Therefore, a 1-year postoperative follow-up period was sufficient to ensure the stability of SSRO with rigid fixation by mini-screws. Due to the different bone-healing processes, a 2-year postoperative follow-up period was necessary to evaluate the stability of IVRO without rigid fixation. From our study, the potency of relapse compared with the amount of setback was 10.2% (1.3/12.8 mm). However, there was no other IVRO study for comparison of the stability during the 2-year postoperative follow-up period.

The postoperative relapse of our patients was about 10%. The orthodontists could manage these relapses to prevent malocclusion, and the facial profiles were accepted by the patients. Therefore, no patients needed a reoperation.

Despite this, the two-jaw surgery is increasingly performed for mandibular prognathism. However, the Asian face is more flat than the Caucasian face, and our surgical relapse is smaller. Therefore, the isolated mandibular setback procedure continues to be the primary choice for our patients.

The 2-year surgical changes (T31) show significant differences in horizontal Me-T31, overbite (T31), Md-Lth (T31), SNB (T31), and Occl-SN (T31) but not in vertical Me-T31 or AFH (T31). This means that the vertical change in Me is smaller and stable.

The relationship between the amount of setback and relapse still is controversial. Kobayashi et al. [9] investigated 44 patients with mandibular prognathism and reported that the magnitude of relapse was proportional to that of the correction in the horizontal direction. Franco et al. [11] explored the factors contributing to the relapse in rigidly fixed mandibular setbacks and concluded that the magnitude of the setback was the single variable that accounted for relapse with single-jaw surgery. However, de Villa et al. [15] identified 20 patients after surgical correction of mandibular prognathism using bilateral sagittal split osteotomy (BSSO) and found no correlation between the magnitude of setback and the amount of relapse at point B and the pogonion during their the long-term follow-up evaluation. Mobarak et al. [16] followed 80 SSRO patients with mandibular prognathism and found the magnitude of mandibular setback to be weakly associated with the amount of horizontal relapse.

In our study, correlation analyses were performed to evaluate the relationship between the magnitude of setback and relapse at point Me. Pearson's correlation coefficient showed no significant relationship between the amount of setback (T21) and relapse (T32). Even the vertical relapse of Me (T32) was significantly correlated with the horizontal relapse of Me (T32). However, the changes in vertical Me (T32) were too small and easily misinterpreted by the clinical relapse. Therefore, most researchers disregard the vertical relapse as a factor contributing to the stability of orthognathic surgery in mandibular prognathism.

Franco et al. [11] determined the factors involved with relapse in rigidly fixed mandibular setbacks and their incidence. They found that postoperative change in the anterior facial height and mandibular length did not significantly influence Pog in the one-jaw group. Neal et al. [17] assessed the stability of the lower labial segment after surgical correction of class 3 skeletal discrepancy. The overbite and SNB tended not to be significantly related to the relapse during the follow-up period.

Our patients showed the same results as those in the previous reports. Although the SN-occlusal plane angle decreased, the mandible showed forward and upward movement. In our finding, the SN-occlusal plane angle (T31) showed a significant change after the 2-year follow-up period. However, there was weak correlation between the SN-occlusal plane angle (T31) and relapse.

Ueki et al. [18] assessed the relationship between the recovery of maximum mandibular opening and the maxillomandibular fixation period after orthognathic surgery. They evaluated 68 patients who had diagnosed mandibular prognathism with or without asymmetry and were divided into four groups (SSRO, IVRO, SSRO with Le Fort I osteotomy, and IVRO with Le Fort I osteotomy). These authors concluded that no significant differences existed between single- and double-jaw surgery in terms of postoperative time-dependent changes in the recovery of MMO. Because there was no fixation between the proximal and distal segments of IVRO, bilateral temporal mandibular joints tended to return gradually to the near original position after 6 weeks of intermaxillary fixation. In our observation, the remodeling of the temporal mandibular joint was a physiologic adaptation to the new position, and no complications were reported by our patients.

The IVRO was our principal treatment for patients with mandibular prognathism because of the reduced risk for damage to the inferior alveolar nerve. The postoperative stability of SSRO and IVRO has been studied by many researchers. Factors contributing to relapse still are controversial. The degree of skeletal changes can differ from case to case, and the reasons still are unclear. Although we investigated postoperative skeletal stability, we cannot ignore the effect of orthodontic treatment. To produce surgically compatible arch forms, presurgical orthodontics is very important for alignment of the teeth of each arch over their own jaw, which leads to immediate postoperative stability. Thus, integrating orthodontic and surgical treatment can improve the quality of the surgical outcome. Postoperative orthodontic treatment still plays a significant role in maintaining satisfactory stability.

References

1. Emrich RE, Brodie AG, Blayney JR (1965) Prevalence of class 1, class 2, and class 3 malocclusions (angle) in an urban population: an epidemiological study. J Dent Res 44:947–953
2. Lew KK, Foong WC, Loh E (1993) Malocclusion prevalence in an ethnic Chinese population. Aust Dent J 38:442–449
3. Ghali GE, Sikes JW Jr (2000) Intraoral vertical ramus osteotomy as the preferred treatment for mandibular prognathism. J Oral Maxillofac Surg 58:313–315
4. Al-Bishri A, Barghash Z, Rosenquist J et al (2005) Neurosensory disturbance after sagittal split and intraoral vertical ramus osteotomy: as reported in questionnaires and patients' records. Int J Oral Maxillofac Surg 34:247–251
5. Lai SS, Tseng YC, Huang IY et al (2007) Skeletal changes after modified intraoral vertical ramus osteotomy for correction of mandibular prognathism. J Plast Reconstr Aesthet Surg 60: 139–145

6. Burstone CJ, James RB, Legan H et al (1978) Cephalometric for orthognathic surgery. J Oral Surg 36:269–277
7. Artun J, Krogstad O, Little RM (1990) Stability of mandibular incisors following excessive proclination: a study in adults with surgically treated mandibular prognathism. Angle Orthod 60:99–106
8. Phillips C, Zaytoun HS Jr, Thomas PM, Terry BC (1986) Skeletal alterations following TOVRO or BSSO procedures. Int J Adult Orthod Orthognath Surg 1:203–213
9. Kobayashi T, Watanabe I, Ueda K (1986) Stability of the mandible after sagittal ramus osteotomy for correction of prognathism. J Oral Maxillofac Surg 44:693–697
10. Krekmanov L, Lilja J, Ringqvist M (1989) Sagittal split osteotomy of the mandible without postoperative intermaxillary fixation: a clinical and cephalometric study. Scand J Plast Reconstr Surg 23:115–124
11. Franco JE, Van Sickels JE, Thrash WJ (1989) Factors contributing to relapse in rigidly fixed mandibular setbacks. J Oral Maxillofac Surg 47:451–456
12. Sorokolit CA, Nanda Ram S (1990) Assessment of the stability of mandibular setback procedures with rigid fixation. J Oral Maxillofac Surg 48:817–822
13. Proffit WR, Phillips C, Dann C IV, Turvey TA (1991) Stability after surgical-orthodontic correction of skeletal Class III malocclusion: I. Mandibular setback. Int J Adult Orthod Orthognath Surg 6:7–18
14. Greebe RB, Tuinzing DB (1982) Overcorrection and relapse after the intraoral vertical ramus osteotomy. Oral Surg Oral Med Oral Pathol 54:382–384
15. de Villa GH, Huang CS, Chen PK, Chen YR (2005) Bilateral sagittal split osteotomy for correction of mandibular prognathism: long-term results. J Oral Maxillofac Surg 63:1584–1592
16. Mobarak KA, Krogstad O, Espeland L, Lyberg T (2000) Long-term stability of mandibular setback surgery: a follow-up of 80 bilateral sagittal split osteotomy patients. Int J Adult Orthodon Orthognath Surg 15:83–95
17. Neal JJ, West CR, Lovius BB (1988) The stability of the lower labial segment following surgical correction of Class III skeletal discrepancy. Br J Oral Maxillofac Surg 26:190–198
18. Ueki K, Marukawa K, Hashiba Y, Nakagawa K et al (2008) Assessment of the relationship between the recovery of maximum mandibular opening and the maxillomandibular fixation period after orthognathic surgery. J Oral Maxillofac Surg 66:486–491