Journal of Cranio-Maxillofacial Surgery (2000) **28**, 343–344

doi:10.1054/jcms.2000.0175, available online at http://www.idealibrary.com on IDEAL®

The submental route revisited using the laryngeal mask airway: a technical note

Francisco Hernández Altemir, Sofía Hernández Montero

Department of Oral and Maxillofacial Surgery (Head: F. Hernández Altemir), Hospital Miguel Servet, Zaragoza, Spain

SUMMARY. **The submental route for endotracheal intubation is well known and this paper reports the use of the same route for the laryngeal mask airway. This technique can be used whenever it is considered too awkward to perform submental, transoral or transnasal endotracheal intubations. When the surgery has been completed, the mouth is left open to allow the laryngeal mask to be removed; it cannot be left in place in cases of intermaxillary fixation. It is necessary to detach the laryngeal mask orally, never submentally, as it is impossible to remove the mask via the submental route. © 2000 European Association for Cranio-Maxillofacial Surgery**

INTRODUCTION

This procedure consists of passing the reinforced tube of a laryngeal mask from intraorally to the submental region after creating a paramandibular, subperiosteal, and sublingual track thus taking advantage of the submental route for endotracheal intubation (*Hernández Altemir*, 1986; *Bennet* et al., 1996; *Ellis*, 1997; *Labbé* et al., 1998; *Prochno* et al., 1996).

MATERIAL AND METHODS

A laryngeal mask with a reinforced tube (LMA-Flexible, Fig. 1; *Brimacombe*, 1999a; *Barley*, 1998) is placed in a supraglottic position. Then a median or paramedian submental incision is performed, by placing it in a wrinkle, scar or wound, if possible. Then, another paramedian incision is made sublingually.

Next, extra- and intraoral incisions are united subperiosteally, taking care not to damage the structures of the floor of the mouth, particularly avoiding the insertions of the geniohyoid and digastric muscles. The cervical superficial aponeurosis and the mylohyoid muscle have to be tunnelled, following which the tube is passed submentally. Finally, the tube of the laryngeal mask is connected and passed to the submental region.

Following placement of the reinforced tube, the laryngeal mask is checked and the tube is fixed with heavy silk (0 or 1) to avoid displacement (Fig. 1).

The head is tilted 30° on the table. Vacuum suction is required, and the operation is performed more carefully than when using endotracheal intubation. At the end of the operation the laryngeal mask is detached and the tube is passed through the floor of the mouth.

In the last year we have operated on three male patients using this technique. The injuries were maxillary, alveolar and nasal fractures that needed packing and would otherwise have been operated on using submental intubation.

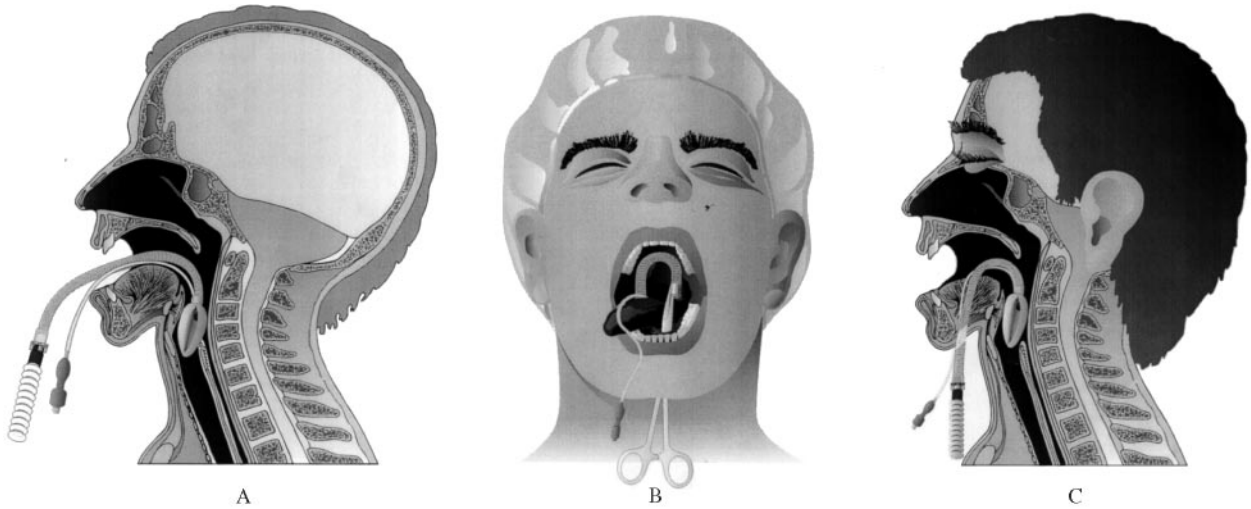

Fig. 1 – Placement of the flexible laryngeal mask using the submental route. (A) Oral insertion of the flexible laryngeal mask. (B) Frontal view of placing the reinforced tube. (C) Lateral view with the flexible laryngeal mask in place.

DISCUSSION

At present, this is an exceptional procedure for specific circumstances and must be performed by surgeons and anaesthetists who are familiar with the LMA and where submental intubation is required. There are several indications:

- In patients with laryngotracheal trauma associated with facial fractures, in whom there is a potential risk of damaging the injured laryngotracheal structures during conventional endotracheal intubation.
- In singers and other voice professionals having had facial fractures, as the conventional intubation could damage the vocal cords and larynx.
- In patients with unstable cervical fractures that have to undergo orofacial surgery.

It is fundamental to place the laryngeal mask correctly in the supraglottic space using the right technique. In our cases, the patient's head could be carefully handled without displacement of the LMA, which was always fixed submentally with a suture.

Fixing the extraoral reinforced tube percutaneously with a suture avoids the laryngeal mask being dislodged from the supraglottic space. If it becomes necessary to turn, flex or extend the head, this has to be performed with great care as the supraglottic region is soft and mobile and not so fixed as the larynx (*Kiyama*, 1999; *Brimacombe*, 1999b; *Keller* and *Brimacombe*, 1999).

This technique avoids interferences between the LMA and the surgical manoeuvres in oral and maxillofacial surgery and circumvents the need for endotracheal intubation or tracheostomy.

Control of the dental occlusion is easy and intermaxillary fixation can be performed with agreement from the anaesthetist.

In case of emergency, the anaesthetist can always perform conventional nasal, oral or submental intubation. A cricothyrotomy or tracheostomy could also be done, if necessary.

Acknowledgements

The authors would like to thank the Department of Anaesthesiology, specificly Dr Ricardo Ruiz and the Intensive Care Unit of the Hospital Miguel Servet (Zaragoza, Spain).

References

Barley F: The flexible LMA: Literature considerations and practical guide. Int Anesthesiol Clin 36: 111–122, 1998

Bennet J, Petito A, Zandsberg S: Use of the laryngeal mask airway in oral and maxillofacial surgery. J Oral Maxillofac Surg 54: 1346–1351, 1996

Brimacombe J: Comparison of the flexible and standard laryngeal mask airways. Can J Anaesth 46: 558–563, 1999a

Brimacombe J: Laryngeal mask usage in the unstable neck. Anesth Analog 89: 536, 1999b

Ellis E: Submental route for endotracheal intubation. In: Fonseca RJ, Walker R, Betts N, Barber D (eds.): Oral and maxillofacial trauma, vol. 1. Advances in Maxillofacial Trauma Surgery, Chapter 13. Saunders, Philadelphia, 1997; 349–350

Keller C, Brimacombe J: The influence of head and neck position on oropharyngeal leak pressure and cuff position with the flexible and the standard laryngeal mask airway. Anesth Analog 88: 913–916, 1999

Kiyama S: Use of a laryngeal mask in a patient with an unstable neck: at induction or during emergency? Anesth Analog 89: 537–538, 1999

Labbé D, Kalluzinski E, Badie-Modiri B, Rakotonirina N, Berenguer C: Intubation sous-mentale en traumatologie cranio-maxillofaciale. Ann Chir Plast Esthet 43: 248–251, 1998

Prochno T, Dornberger I, Esser U: Management of panfacial fractures, also an intubation problem. HNO 44: 19–21, 1996

Hernández Altemir F: The submental route for endotracheal intubation. A new technique. J Maxillofac Surg 14: 64–65, 1986

Francisco Hernández Altemir MD
C/Fray Luis Amigó
n° 8, 0-B. Zaragoza
Spain

Tel: +34976270719
Fax: +34976387553

Paper received 23 February 2000
Accepted 21 November 2000